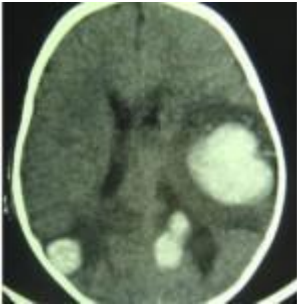


# A case of a 3 month old infant with bloody urine and stools



- [Patient presentation](#)
- [History](#)
- [Differential Diagnosis](#)
- [Examination](#)
- [Investigations](#)
- [Discussion](#)
- [Treatment](#)
- [Final outcome](#)
- [References](#)
- [Evaluation - Questions & answers](#)
- [MCQ](#)

## Patient presentation

A three month old male infant presents to the emergency department with a one day history of haematochezia and haematuria, accompanied by a diffuse rash and shortness of breath.

### Acknowledgement

*This case study was kindly provided by Dr Bhadrish J Mistry, Paediatrician, Department of Paediatrics, Chris Hani Baragwanath Hospital and the University of Witwatersrand.*

## Partnership

We have partnered with The International Union of Basic and Clinical Pharmacology (IUPHAR) to bring you in-depth information about drugs and pharmacology with links to the Guide to ImmunoPharmacology.

## History

A three month old male infant was brought into the emergency department by his mother with a first time presentation of haematochezia and haematuria, noted in his nappy. She also complained that he was short of breath and she had noted a rash that had appeared on his face, body and legs that morning.

There was no accompanying haematemesis, diarrhoea, vomiting or fever.

She also noted that he was not feeding as well as usual.

### Past Medical History

The infant had been admitted to hospital in Zimbabwe at 2 months of age for “breathing problems” but no diagnosis had been given. During his admission he was transfused with packed red cells for anaemia and was discharged on iron and bactrim.

### Birth History

Mother was 41 years old, P3G4

At 24 weeks gestational age, the mother was treated with 3 days of [chloroquine](#) for a possible case of malaria. The symptoms resolved and she went on to have an uneventful remainder of her pregnancy. The infant was born term, NVD with no complications during the delivery.

The infant was both breast and formula fed, duration was not specified.

## **Social History**

The family are from Zimbabwe, now living in Johannesburg for the last month. The infant was born in Zimbabwe and lived there for the first two months of his life.

He has three older siblings aged 3, 6 and 8 who are all well

## **Vaccinations**

Up to date

## **Medication**

Currently completing a course of iron and bactrim. No history of any traditional medication use (orally or via enema).

## **Allergies**

None known

# **Differential Diagnosis**

- Post streptococcal glomerulonephritis
- Perforated meckel's diverticulum
- Salmonella
- Shigella
- ITP
- DIC
- Neonatal Lupus Erythematosus (NLE)

# **Examination**

## **Vitals**

Heart Rate- 120 beats per minute Blood Pressure- 80/50  
Respiratory rate- 40 breaths per minute Temperature- 36.5°C

## **Anthropometry**

Weight: 4.4kg (75% expected weight for age)  
Length & head circumference: Normal

## **General**

Marked pallor

No jaundice

No significant lymphadenopathy

No oedema

## **Subtle dysmorphic features:**

- Biparietal prominence
- Epicanthic folds
- Almond shaped eyes

Subconjunctival haemorrhage right eye

No cataracts

No subaponeurotic haemorrhage or cephalhaematoma

## **Skin**

Diffuse petechiae and purpura involving face, trunk and limbs

No ecchymosis

## **Abdomen**

Mildly distended but soft & non tender

Hepatomegaly: 4-5cm firm, non tender

Splenomegaly: 2-3cm & firm

Bowel sounds present

## **Chest**

Moderate respiratory distress

Clear on auscultation

## **Cardiovascular**

Tachycardia & hypotensive

No evidence of congestive cardiac failure

## **Neurological**

No focal neurological signs

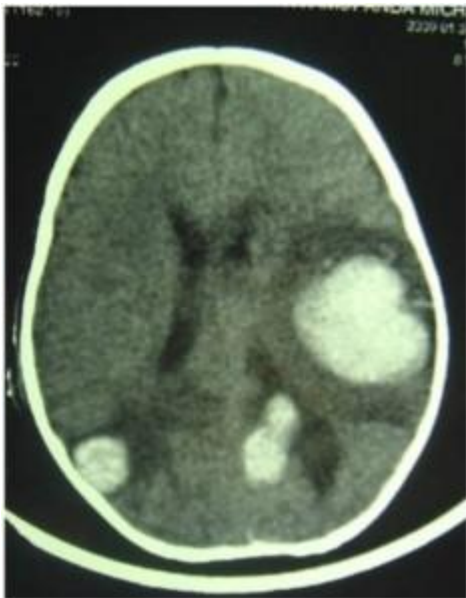
## **Musculoskeletal**

No abnormalities

# Investigations

	Values	Normal Limits
WBC	3.1 (diff 1.6 neutrophils and 2.8)	(4-12x10 <sup>9</sup> /l)
HB	4.0999999999999996	(12.1-15.2g/l)
MCV	78.8	(80-96 fl)
Platelets	15	(140-45x10 <sup>9</sup> /l)
Reticulocyte count	5.6000000000000001E-2	(0.8-4% RBC)
Smear:		
Normochormic, normocytic anaemia with spherocytes		
Red cell fragments		
Left shift in neutrophils		
LDH	953	(70-250 u/l)
Haptoglobin (free serum)	0.45	(27-139 mg/dl)
Coombs direct	Positive	
INR	0.9	(1.0-1.3)
PTT	30	(23-31)
WR	Negative	
TPHA	Negative	
Toxoplasmosis	Negative	
Rubella	Negative	
Parvovirus B19	Negative	
Malaria	Negative	
Herpes	Negative	
CMV	Negative	

	Values	Normal Limits
Total bilirubin:	22	(3-17 umol/l)
Unconjugated bilirubin:	15	(0.0-0.3 mg/dl)
ANA	Positive	
Anti Ro:	104	
Anti La:	156	
ACLA: IgG	18	
ACLA IgM	12	
B2 glycoprotein	Normal	



### **Mothers Results**

WR: negative

ANA: Positive, titre 1280 speckled pattern

dsDNA: negative

Anti Ro: 96

Anti La: 144

### **Abdominal ultrasound**

Features of hepatomegaly

Splenomegaly with multiple microabscesses

Very thickened bladder with dilated post urethra

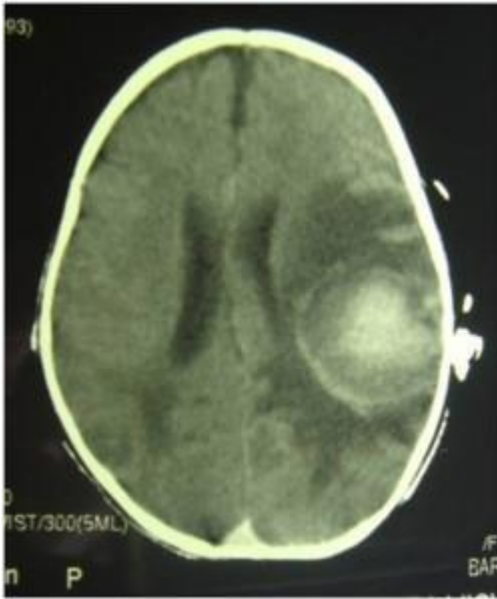
### **Bone marrow trephine**

Reactive changes in RBC and megakaryopoietic precursor

Focus granulation tissue secondary to previous haemorrhage

No granulomatous infiltration

No neoplastic infiltrate



### **CT Brain**

Day 16 post admission, infant developed a seizure.

CT scan shows multiple parenchymal bleeds and oedema

29 Days later CT scan shows decreased bleeding and oedema.

## **Discussion**

Neonatal lupus erythematosus (NLE) is an uncommon condition associated with maternal anti-Ro and anti-La autoantibodies. These autoantibodies are passively transferred to the foetus through the placenta, and once in the foetal circulation promote the development of NLE by binding to antigen. Anti-Ro and anti-La autoantibodies bind to nuclear antigens translocated to the cell membranes of apoptotic cells, in particular myocytes and keratinocytes. Macrophages expressing Fc receptors recognise bound IgG and become activated and initiate inflammatory responses. This antigen binding is found to cause cutaneous lupus lesions, third-degree heart block, cardiomyopathy, hepatobiliary disease, and thrombocytopenia or other haematologic cytopenias. In this

case study we see cutaneous and hepatic involvement accompanied by a pancytopenia. Studies have found that anti La antibodies are associated with cutaneous lupus and anti Ro antibodies are associated with congenital heart block. Anti-platelet antibodies are present which cause destruction of platelets while anaemia is caused by both antibodies and haemorrhage. In this case haemorrhage is evidenced by haematochezia, haematuria and intracranial bleeds. Pancytopenia is also further exacerbated by hypersplenism which can result in patients undergoing splenectomy if the condition is not resolved. Typically only one organ is affected in NLE, but any combination of organ involvement may occur. Pregnant women with anti-Ro and anti-La antibodies have a 5-20% risk of having a child/children with NLE, with the risk being highest in mother's with high titre antibodies.

Although during pregnancy, maternal IgG autoantibodies are transported to the foetus via the placenta after birth the foetal levels of Ro and La IgG autoantibodies are found to rapidly decrease suggesting that after placental detachment the source of immunoglobulins is markedly decreased or ended. Although breast milk also contains IgA and IgG autoantibodies the dose or foetal uptake is not enough to reach detectable levels.

The most common severe manifestation of neonatal lupus is third-degree heart block, which usually begins during the second trimester of gestation and once established is irreversible. This is thought to occur from the inflammatory process that results from the macrophages expressing Fc receptors which recognise the bound IgG. The secretion of pro-inflammatory cytokines causes inflammation and ultimately fibrosis in the cardiac tissue. These patients require the insertion of a pacemaker to maximize heart function. If cardiomyopathy is also present this can be fatal.

Otherwise for the most part NLE is transient. The cutaneous lesions are what give the neonatal "lupus" its name, as the



lesions are clinically and histologically consistent with cutaneous lupus having the major features of keratinocyte damage and mononuclear cell infiltrate. Skin lesions often present at a few weeks of life, but may be present at birth. Spontaneous resolution within weeks or months without permanent residua is the expected outcome. Affected individuals tend to be healthy later in childhood. There does however appear to be an increased risk for children who have had NLE to develop autoimmune diseases later in childhood or adulthood such as juvenile rheumatoid arthritis, Hashimoto thyroiditis and diabetes mellitus.

At present, practices and opinions differ regarding recommendations for prophylactically treating anti-Ro positive women during pregnancy. What is generally agreed on is that if systemic corticosteroids are given, [dexamethasone](#) or [betamethasone](#) are better choices than [prednisone](#) or [prednisolone](#), as they are not inactivated by placental enzymes and so reach the fetal circulation largely intact.

It is quite often the case that autoimmunity in the mother is not detected until the birth of her first child with NLE. Several studies indicate that, with time, the mothers who were initially asymptomatic eventually develop signs and symptoms of autoimmunity themselves, in particular Sjögren syndrome, systemic lupus erythematosus and undifferentiated connective tissue disease.

## Download images for this case



### [Neonatal Lupus](#)

1 file(s) 266.64 KB

[Download](#)

# Treatment

Initial treatment was packed red blood cells & platelet transfusions for the pancytopenia. He was then given intravenous immunoglobulin (IVIg) to create a dilutional effect and high pulse dose pulse of [methylprednisolone](#) and oral [prednisone](#).

The seizures were treated with [phenobarbitone](#).

Gradually the cytopenias responded to therapy with resolution of the anaemia and normalisation of platelet count.

Post transfusion and glucocorticoid blood smears showed resolution of fragments and spherocytes.

## Discharge blood results:

- Hb:11,8
- MCV: 79,5
- Platelets: 181
- Neutrophil: 3.8
- Anti Ro: 18
- Anti La: negative

Note: There are no established guidelines or consensus for effective treatment and management of this haematologic disease.

## General recommendations are to try combinations or isolated forms of the following:

- Glucococorticoids
- IVIG
- Plasmapheresis
- Plasma exchange

**Download images for this case**



## [Neonatal Lupus](#)

1 file(s) 266.64 KB

[Download](#)

### **Final outcome**

The child continues to improve and is anticipated to make a full recovery.

### **Download images for this case**



## [Neonatal Lupus](#)

1 file(s) 266.64 KB

[Download](#)

### **References**

1. C McGeachy et al (2009). Anti-RNP neonatal lupus in a female newborn. *Lupus*; 18; 172-174

[Link to Abstract](#)

2. R Klauninger et al (2009). Serologic follow-up of children born to mothers with Ro/SSA autoantibodies. *Lupus*; 18; 792-798

[Link to Abstract](#)

3. Lela A. Lee. (2009) The clinical spectrum of neonatal lupus. *Archives of Dermatological Research*. 301:107-110

[Link to Abstract](#)

# Download images for this case



## Neonatal Lupus

1 file(s) 266.64 KB

[Download](#)

Evaluation – Questions & answers

### **What is the diagnosis?**

A 3 month old male with Neonatal lupus Erythematosus (NLE) presenting with thrombocytopenia, anaemia. neutropenia and antiphospholipid antibodies. Complicated by haematochezia, haematuria and intracranial haemorrhage

### **Which autoantibodies are associated with NLE?**

Anti-Ro and anti-La autoantibodies

### **What is the mechanism of disease?**

Passive transfer of IgG anti-nuclear antibodies specifically to Ro and La proteins through the placenta. Once in the foetal circulation these antibodies promote the development of NLE by binding to antigen. Anti-Ro and anti-La autoantibodies bind to nuclear antigens translocated to the cell membranes of apoptotic cells. Macrophages expressing Fc receptors recognise bound IgG and become activated.

### **Which organ systems are affected?**

Cardiac, dermatologic, hepatobiliary and haematologic.

### **What are the long term consequences of NLE on the affected infant?**

For the most part NLE is transient, however if third degree heart block (due to inflammation and fibrosis) develops this is irreversible requiring the implantation of a pacemaker and if coupled with cardiomyopathy may be fatal.

There also appears to be an increased risk for development of autoimmune diseases later in childhood or adulthood.

## **What causes anaemia, thrombocytopenia and occasionally pancytopenia in NLE?**

Anti-platelet antibodies and anti- red cell antibodies are a common cause of thrombocytopenia and anaemia. Anaemia can also result from haemorrhage, while pancytopenia is most likely due to hypersplenism

## **What investigations can be carried out to assess pancytopenia?**

Investigations that can be carried out include:

- FBC
- Bone marrow trephine biopsy
- LDH where a high reading indicates general cell destruction
- Haptoglobin which decreases when consumed by high release of haemoglobin
- Coombs test which identifies anti-red cell antibodies in plasma – i.e. proof of circulating anti-red cell antibodies

## **Download images for this case**



### **[Neonatal Lupus](#)**

1 file(s) 266.64 KB

[Download](#)

## **Multiple Choice Questions**

**Earn 1 HPCSA or 0.25 SACNASP CPD Points  
– [Online Quiz](#).**

## Download images for this case



### [Neonatal Lupus](#)

1 file(s) 266.64 KB

[Download](#)