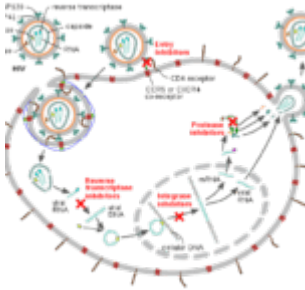


# A sudden turn of events after successful therapy



- [Patient presentation](#)
- [History](#)
- [Differential Diagnosis](#)
- [Examination](#)
- [Investigations](#)
- [Discussion](#)
- [Treatment](#)
- [Final outcome](#)
- [Evaluation - Questions & answers](#)

## Patient presentation

HIV positive 7 year old female, classified as [WHO Stage III](#). She has been on antiretrovirals for 9 months. She presents with a moderate pyrexia and severe weakness and is reported to have dark urine and pale stools.

### Acknowledgement

*This case study was kindly provided by the Wits Paeds HIV Clinics.*

## History

At age 6 years the child was brought into the clinic by her grandmother with unexplained persistent diarrhoea which had

lasted for more than 2 weeks. Her grandmother also complained that she did not seem to be growing despite the family always having enough to eat. The child was admitted to hospital which resulted in a 2 month stay.

At this time she was assessed clinically as [WHO stage III](#) based on the duration of her diarrhoea, failure to gain weight and the prolonged hospital admission.

After discussing treatment and counseling with her grandmother, the child was prescribed highly active [antiretroviral therapy](#) (HAART) – 3TC, d4T and efavirenz (EFV), cotrimoxazole and multivitamins. During the first few days of starting HAART she developed a brief self-resolving rash. Other than this initial incident she has responded well to her treatment with no reported side effects or adverse events.

She has no history of TB or liver disease.

## Differential Diagnosis

- Acute hepatitis- prodrome phase of malaise, nausea, vomiting and fever. Followed by the appearance of dark urine and jaundice and tender hepatomegaly.
- Epstein Barr Virus (EBV)- typically present with fatigue, fever, lymphadenopathy and pharyngitis. Hepatomegaly and jaundice occur less commonly.
- Cytomegalovirus (CMV)- febrile illness with hepatitis, jaundice and rash.
- IRIS
- Drug toxicity

## Examination

- Axillary temperature 39°C
- Evidence of jaundice seen in sclera
- Mild discomfort in right upper quadrant and on abdominal

examination, hepatomegaly noted.

- No skin rashes or discolouration noted

The remainder of the examination is nil of note

## Review of Systems

Pale stools and dark urine

## Investigations

<b>Prior to starting HAART</b>	
Baseline CD4	311 (13%)
ALT	29 (5-45 U/L)
Current Results:	
Liver Function Test	
Total Bilirubin	221 (3-18 umol/l)
Direct Bilirubin	193 (0-5 umol/l)
ALP	378 (30-12 U/L)
GGT	149 (5-35 U/L)
ALT	268 (5-45 U/L)
AST	388 (5-45 U/L)
INR	3.68 (1.0)
Lactate	1.5 (<1.5 mmol/l)
Hepatitis A virus (HAV)	Anti HAV IgM – Negative
Hepatitis B virus (HBV)	Anti-HBc IgM and HBsAG – Negative
Hepatitis C virus (HBC)	Anti-HCV – Negative
EBV	VCA IgM – Negative
CMV	CMV IgM and IgG - Negative

# Discussion

## Based on the results obtained:

- Acute hepatitis- excluded as all tests negative
- Epstein Barr Virus (EBV)-excluded as result was negative.
- Cytomegalovirus (CMV)- excluded as result was negative
- IRIS – unlikely because symptoms did not occur within the first month of treatment
- Drug toxicity – most likely cause although no liver biopsy was performed

## The principles of drug toxicity management (based on WHO guidelines):

- Estimate severity of the effects
- Could drugs other than ARVs cause these symptoms? Evaluate concurrent medications, and establish whether the toxicity is attributable to an ARV or due to other drugs taken at the same time
- Consider other diagnoses, including IRIS and hepatitis infection especially in a child who develops jaundice.
- Manage the adverse event according to the severity:

Maintain regimen for Grade 1 or 2

Substitute regimen for Grade 3

Stop all drugs for Grade 4

Grade 1 (mild)	Grade 2 (moderate)	Grade 3 (severe)	Grade 4 (life threatening)
Mild Reactions	Moderate reactions	Severe Reactions	Severe life-threatening reactions

<b>Grade 1 (mild)</b>	<b>Grade 2 (moderate)</b>	<b>Grade 3 (severe)</b>	<b>Grade 4 (life threatening)</b>
<p>These reactions are bothersome but they do not require a change in therapy.</p>	<p>Some moderate reactions (e.g. lipodystrophy or peripheral neuropathy) require substitution. For other reactions continue ART as long as is feasible; if the patient does not improve on symptomatic therapy, consider single drug substitution.</p>	<p>Substitute the offending drug without discontinuing ART</p>	<p>Immediately discontinue all ARV drugs and manage the medical event (i.e. symptomatic and supportive therapy) and reintroduce ARV's using a modified regimen (i.e. substituting another ARV drug for the offending drug) when the patient's condition is stable.</p>
<p>Mild discomfort that does not limit activity.</p>	<p>Some limitation in activity but no medical intervention needed.</p>	<p>Marked limitation in activity. Medical care required.</p>	<p>Extreme limitation in activity. Hospitalization required.</p>

Grade 1 (mild)	Grade 2 (moderate)	Grade 3 (severe)	Grade 4 (life threatening)
Published by International Centre for AIDS care and treatment programs-School of Public Health, Columbia University.			

## Treatment

Our patient was assessed with a Grade 4 severity of toxicity and all medication was stopped. This included the ARVs, co-trimoxazole and the multivitamins. All medication was stopped at the same time.

The patient was then continuously observed and liver function results recorded and monitored until baseline values were attained.

## Final outcome

- Patient was graded as Grade 4 severity of [drug toxicity](#).
- All drugs were stopped at the same time and she made a slow recovery over 3 months.
- All of her liver values normalised and she followed a generally uneventful clinical course.
- Co-trimoxazole toxicity was suspected so she was not re-challenged with the drug.
- Given the evidence for immune restoration based on CD4 recovery PCP prophylaxis was not reinstated.
- She was restarted on d4T, 3TC and EFV without worsening

of the hepatotoxicity, up to five months of follow up

## **Evaluation – Questions & answers**

**What is the most likely cause of the symptoms this patient is suffering from?**

Drug Toxicity

**What are the side-effects and toxicities of ARVs within the first few weeks of starting therapy?**

- Gastrointestinal toxicities include nausea, vomiting and diarrhoea. These side-effects are usually self-limiting and require symptomatic treatment only.
- Rash and liver toxicity are more common with the NNRTI drugs but are also seen with certain NRTI drugs such as abacavir (ABC) and some protease inhibitors (PIs).
- A lead-in dose is used for nevirapine (NVP) to lower the risk of toxicity.
- In case of mild-to-moderate rash and liver toxicity, antiretrovirals (ARVs) can be continued under close follow up, and symptomatic treatment and supportive care given.
- Severe rash and liver toxicity (ALT >5 ULN) can be life-threatening and NVP should be substituted with another drug.
- CNS toxicity from Efavirenz (EFV) can be self-limiting. Because EFV can cause dizziness most physicians advise that it should be taken at night.
- ABC hypersensitivity usually occurs within the first 6 weeks and can be life-threatening. ABC must be stopped and re-challenge never attempted.

**What are the side-effects and toxicities of ARVs after 4 weeks of starting therapy?**

- Drug-induced bone-marrow suppression such as anaemia and

neutropenia are most commonly seen with AZT.

- Other causes of anaemia should be looked for and treated.
- Asymptomatic mild anaemia is common.
- If there is severe anaemia (Hb

### **What are the side-effects and toxicities of ARVs from 6-18 months after starting therapy?**

- Mitochondrial dysfunction is primarily seen with the NRTI drugs; these include lactic acidosis, hepatic toxicity, pancreatitis, peripheral neuropathy, lipoatrophy and myopathy.
- Lipodystrophy is frequently associated with d4T use and can cause permanent disfigurement.
- Lactic acidosis is rare and can occur at any time. It is particularly associated with d4T use. Severe lactic acidosis can be life-threatening.
- Metabolic disorders are more common with PIs and include hyperlipidaemia, fat accumulation, insulin resistance, diabetes and osteopenia.
- Stop the NRTI and switch to another drug with a different toxicity profile

### **What are the side-effects and toxicities of ARVs after a year of starting therapy?**

- Nephrolithiasis is commonly seen with indinavir (IDV).
- Renal tubular dysfunction is associated with tenofovir disoproxil fumarate (TDF).
- Stop the PI and switch to another drug with a different toxicity profile.

### **How is ARV toxicity severity managed?**

#### **Grade 1 (mild)**

Mild reactions. These are bothersome but they do not require a change in therapy



**Grade 2 (moderate)**

Moderate reactions. Some moderate reactions (e.g. lipodystrophy or peripheral neuropathy) require substitution. For other reactions continue ART as long as is feasible; if the patient does not improve on symptomatic therapy, consider single drug substitution.

**Grade 3 (severe)**

Severe reactions. Substitute the offending drug without discontinuing ART.

**Grade 4 (life threatening)**

Severe life-threatening reactions. Immediately discontinue all ARV drugs and manage the medical event (i.e. symptomatic and supportive therapy) and reintroduce ARVs using a modified regimen (i.e. substituting another ARV drug for the offending drug) when the patient's condition is stable. Hospitalization required.

Published by International Center for AIDS care and treatment programs- School of Public Health, Columbia University.

**What are the indications for co-trimoxazole therapy?**

Co-trimoxazole, a fixed-dose combination of sulfamethoxazole and trimethoprim, is a broad-spectrum antimicrobial agent that targets a range of aerobic gram-positive and gram-negative organisms, fungi and protozoa and is an integral part of preventing *Pneumocystis jirovecii* pneumonia (PCP) and toxoplasmosis. The drug is widely available in both syrup and solid formulations at a low cost in resource-limited settings. Co-trimoxazole is on the essential medicines list of most countries and indicated for opportunistic infections in immunocompromised patients.

**What are the side effects of co-trimoxazole?**

Although side effects to co-trimoxazole do not occur as frequently as side effects to ARVs they are important to consider when there is unexplained hepatotoxicity or skin rash.

Co-trimoxazole is composed of two parts, trimethoprim and sulfamethoxazole (to find out more). Side effects of the trimethoprim component occur more frequently than side effects to sulfamethoxazole. The effects of trimethoprim are dose dependent, usually not severe, rarely of clinical significance and easily treated or prevented by folate supplementation. In

contrast the side effects of sulfamethoxazole occur less often but are more severe. They are similar to the hematological side effects of other sulfonamide drugs which include hepatotoxicity, skin rash, blood dyscrasias, nephritis and cardiotoxicity. They are unpredictable and mostly mediated by the immune-system. They may be of life-threatening severity.

### **How do you manage co-trimoxazole toxicity?**

Termination of exposure to the drug is the best way to treat this. Diagnostic re-challenge with sulfonamides in patients who have survived severe reactions can be associated with significant morbidity and potential mortality and therefore should not be done. If antibacterial cover is still required you can try dapsone 2 mg/kg once daily, as an alternative to co-trimoxazole. However some children cannot tolerate either drug. No alternative recommendation can be made in resource-limited settings for children who cannot tolerate either drug

### **What is the mechanism of action of co-trimoxazole toxicity?**

Sulfonamides are metabolized by several pathways, of which there are two known metabolic pathways involved in predisposing people to toxicity (to find out more). These include the rate of acetylation where sulfonamides are metabolized by N-acetylation and oxidation forming potentially toxic metabolites and cytochrome P-450 which is involved in generating the potentially cytotoxic intermediate hydroxylamine. Resulting adverse reactions include hepatotoxicity, skin rash, blood dyscrasias, nephritis and cardiotoxicity and may be potentially life threatening.

The effects of these altered function is that patients who are slow acetylators develop toxicity because more drug is available for metabolism. The other effect is the production of hydroxylamine from cytochrome P-450 mixed-function oxidases. This metabolite is partly detoxified by conjugation with glutathione however people who develop toxicity to cot-trimoxazole have lymphocytes with glutathione synthetase deficiency.

In addition to chemical reactivity to these by products there can be a cell mediated immune response involving protein conjugation to the chemical by products.