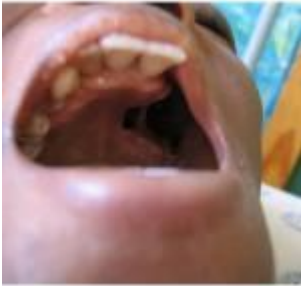

A 10 year old girl with a hard palate defect



- [Patient Presentation](#)
- [History](#)
- [Differential Diagnosis](#)
- [Examination](#)
- [Investigations](#)
- [Discussion](#)
- [Treatment](#)
- [Final Outcome](#)
- [References](#)
- [Evaluation - Questions & answers](#)

Patient Presentation

A 10 year old girl recently diagnosed with HIV ([WHO stage 4](#)), presents with a 12 day history of diarrhoea, vomiting, difficulty swallowing and abdominal cramps. She has remained afebrile throughout her illness.

Acknowledgement

This case study was kindly provided by Dr Bhadrish J Mistry, Paediatrician, Department of Paediatrics, Chris Hani Baragwanath Hospital and the University of Witwatersrand.

History

Six months ago she had been admitted to her local hospital following a 5 day history of swollen painful gums with painful swelling of the left upper jaw and cheek. She was diagnosed with acute necrotising ulcerative gingivitis (cancrum oris).

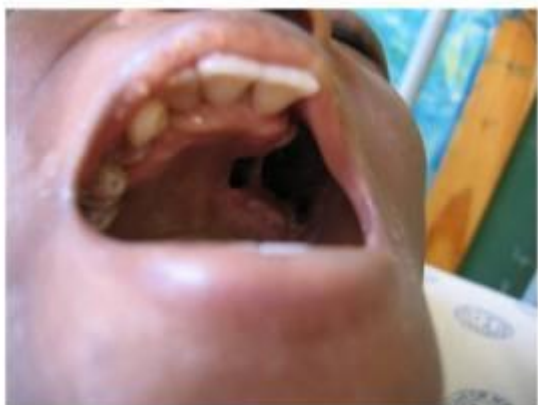A month later she was started on anti-[TB treatment](#) based on scanty AFB found in her sputum, but she soon defaulted on her treatment.

2 weeks ago she was diagnosed with HIV (WHO 4). She was found to be severely wasted, with a CD4 count of 0,48% (4cells/ul) and a viral load of 140 000 copies/ml.

Differential Diagnosis

- Chronic gastroenteritis
- MDR TB
- Hepatitis
- Mycobacterium Avium Complex
- CMV
- EBV

Examination



General

- Cachectic (weight 44% expected weight for age) and stunted
- Well hydrated
- Not jaundiced or pale
- Generalised significant lymphadenopathy
- No petechia or purpura

Oral

- Extensive oral candidiasis, with limited opening of the mouth
- Hard palate ulcerative lesion extending from the alveolus to the palatine process of the maxilla to the palatoglossal arch
- The defect has a rounded edge and a small posterior area with exudates

Abdomen

- Scaphoid, non tender
- 3-4 cm firm hepatomegaly but no splenomegaly
- No ascites

Respiratory

- Not in respiratory distress
- No features of chronic lung disease

Cardiovascular

- No abnormalities detected
- No features of cor pulmonale

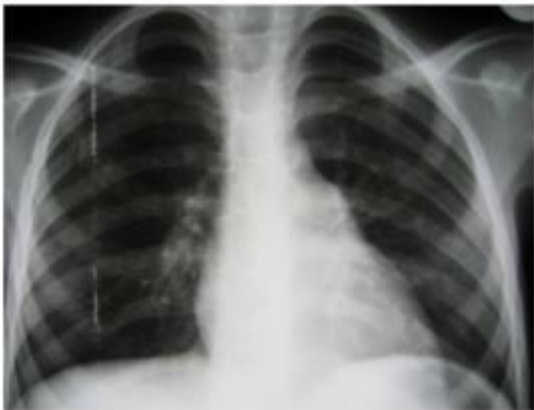Neurological

No focal signs

Dermatological

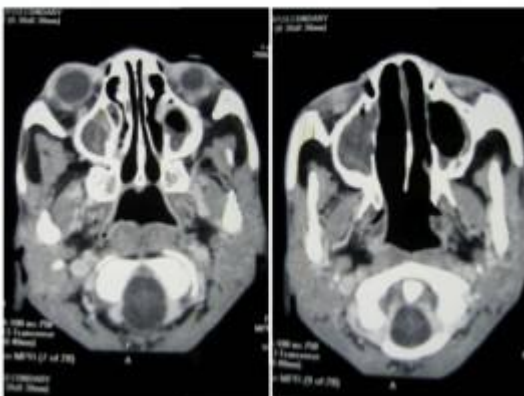
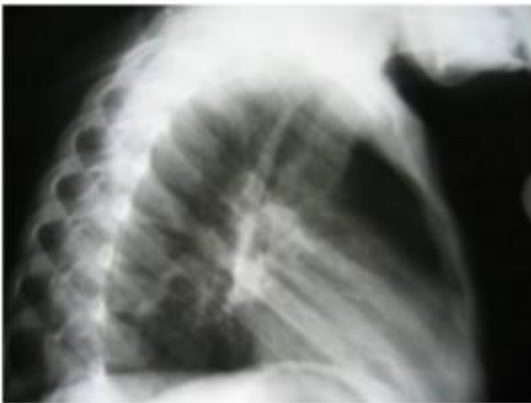
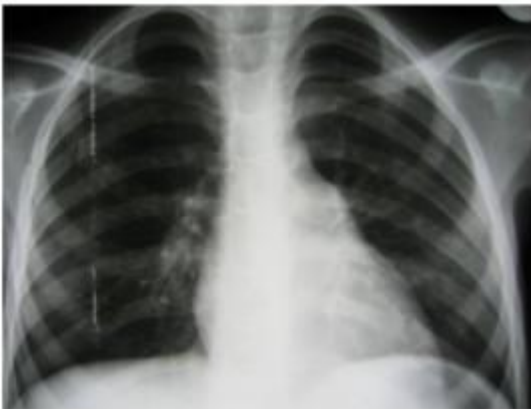No rashes or kaposi lesions

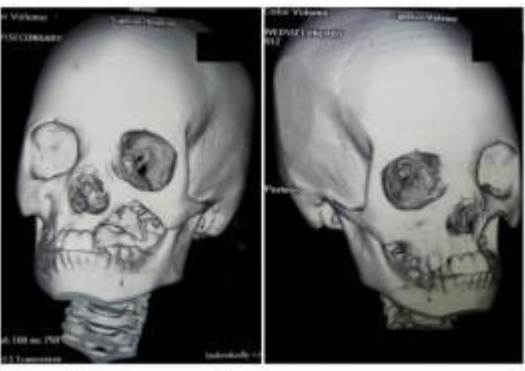
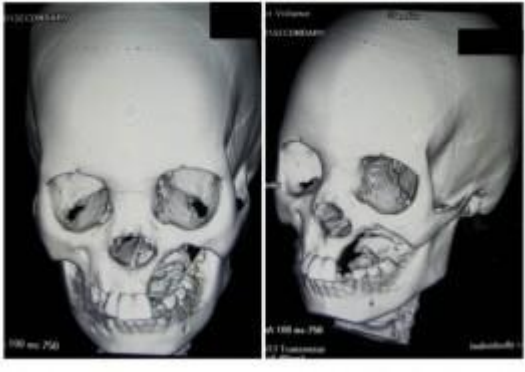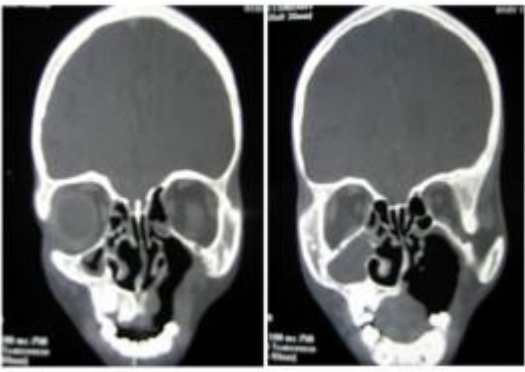
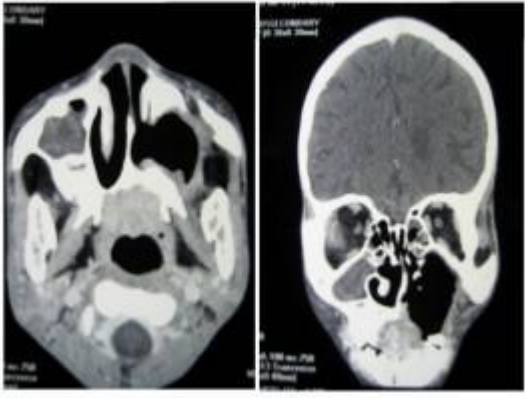
Investigations



Urine Dipstick	NAD
Chest X-Ray	PA and Lateral
FBC:	
WCC	4.5999999999999996
Hb	8.1999999999999993
MCV	103
Plt	357
Differential:	
Neutrophils	85
Monocytes	5
Lymphocytes	9
CRP:	58
U/E:	
Sodium	136
Potassium	2.5
Chloride	102
C02	17
Urea	3.5
Creatinine	37

Urine Dipstick	NAD
Iron Studies:	
Fe	5.2
TF	1.100000000000000001
% Sat	14
Ferritine	544





Hepatitis Studies: Negative

CMV (PP65): Negative

EBV: Negative

Abdominal Ultrasound

Liver : R lobe 13.5cm, L lobe 12.7cm, echogenic but no focal lesions or dilated ducts

Normal gallbladder, pancreas & spleen

Normal kidneys

No free fluid

Mesenteric & para-aortic nodes noted

Liver Biopsy

Not done

CT Scan of Face and Brain

Shows destruction of the left maxilla

Biopsy of the Hard Palate

Features of acute on chronic inflammation

No evidence of granulomas

Culture of Hard Palate Biopsy

Isolated Mycobacterium Avium Complex and Candida Krusei

3 Sputum Specimens

[Ziehl-Neelsen Stain – Numerous AFBs](#)

Culture isolated Mycobacterium Avium Complex (MAC)

2 TB Bactec Specimens

Isolated AFB positive – MAC

Bone Marrow Aspirate & Trepine

Showed active haematopoiesis

Ill-defined granuloma showing epithelioid histiocytes

Decreased megakaryocytes, granulopoiesis & erythropoiesis

Discussion

There are many causes of oral ulcerative lesions. Listed here are the ones that are most commonly encountered:

- Lymphoma
- Necrotising Ulcerative Gingivitis
- Necrotizing Ulcerative Peridontitis – associated with severe pain and bleeding, rapid loss of bone and soft tissue
- Necrotising Stomatitis
- Mycobacterium Avium Complex (MAC) this is quite rare
- The herpes group of infections
- CMV – Necrotic with a white halo
- Fungal infections including Histoplasmosis and Cryptococcosis
- Aphthous ulcers
- Neutropenic ulcerationis
- Acute Necrotising Gingivitis (risk factors include poverty, malnutrition, poor oral hygiene and infectious diseases)

MAC oral manifestation

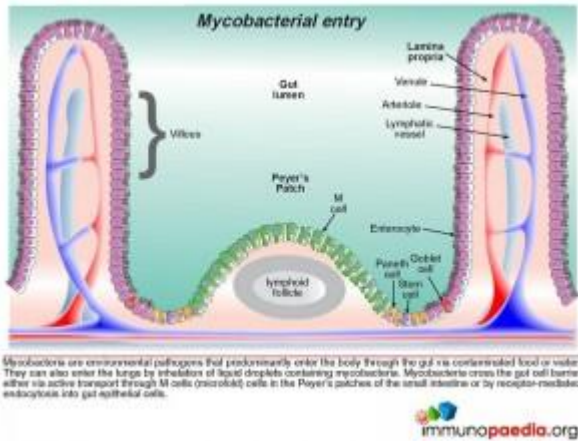
There is not a lot of information regarding the oral manifestation of MAC however, two reported adult cases have shown it to first present as a palatal and gingival ulcerative lesion with firm borders and a necrotic centre that extended down to the bone and later invading the maxillary, frontal, sphenoid and ethmoid sinuses. MAC was isolated from sputum, blood, bone marrow and the lesion itself in both patients.

Epidemiology of MAC

This is a multiple related species of nontuberculous mycobacteria including *M. avium*, *M. intracellulare* and *M. paratuberculosis*. It is the second most common opportunistic infection found in HIV infected children.

It is a ubiquitous pathogen found throughout the environment

often in contaminated water and food, transmitted via ingestion, inhalation or inoculation, leading to GIT and pulmonary disease. Although disseminated infection rarely occurs during the first year of life it occurs more frequently thereafter.

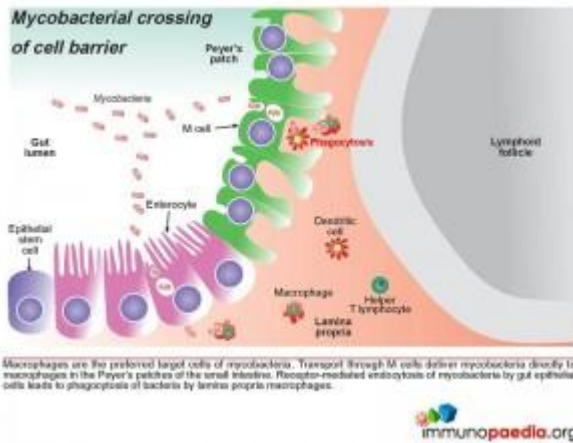


Risk factors for MAC

- CD4 count 50 cells/ul (and in children can occur at higher CD4 counts)
- High viral load 100 000 RNA copies/ml
- Prior opportunistic infections (esp CMV disease)

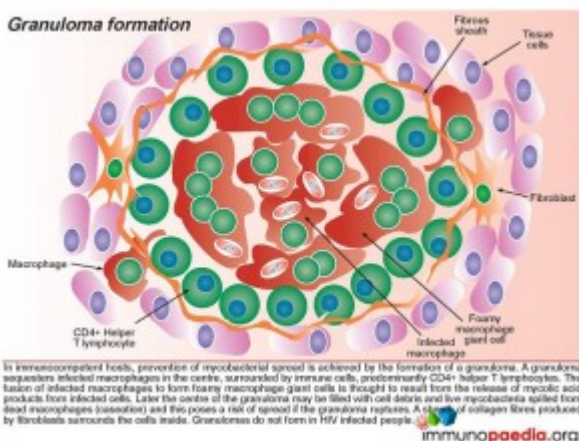
Pathophysiology

- The disease is not due to reactivation but rather recent acquisition.
- Typically the host reaction is minimal with little occurrence of tissue destruction.
- The organism adheres to the gut wall with rapid penetration of the intestinal mucosa.
- Macrophages are the preferred target cells of mycobacteria. The bacteria are transported through M cells directly to macrophages in the Peyer's patches of the small intestine. Where receptor-mediated endocytosis of mycobacteria by gut epithelial cells leads to phagocytosis of bacteria by lamina propria macrophages.



- Phagocytosis by macrophages in advanced AIDS is usually impaired.
- Phagocytosis of Mycobacteria by macrophages internalises bacteria in a membrane-bound phagosome. Under normal conditions, the phagosome fuses with a lysosome forming a phagolysosome which kills the bacteria. Mycobacterium tuberculosis and Mycobacterium avium have evolved mechanisms to prevent the fusion of the lysosome with the phagosome thus evading host immune defenses by allowing the bacteria to survive and multiply in the phagosome.

In this way they can spread to other parts of the body when the macrophages migrate to other tissues.



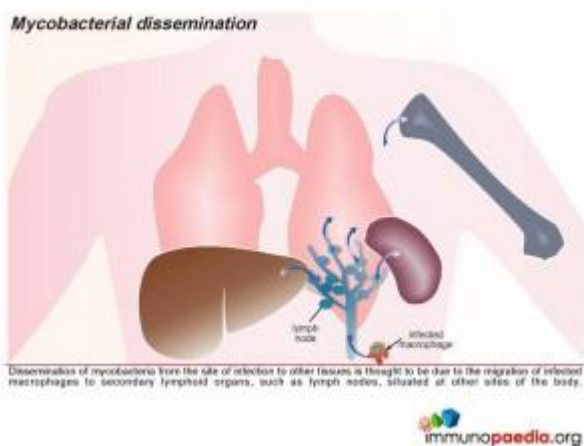
- In immunocompetent hosts, prevention of mycobacterial spread is achieved by the which sequesters infected macrophages in the centre, surrounded by predominantly

CD4+ helper T lymphocytes. The infected macrophages fuse and form giant cells. Later the centre of the granuloma may be filled with cell debris and live mycobacteria spilled from dead macrophages which poses a risk of spread if the granuloma ruptures. A sheath of collagen fibres produced by fibroblasts surrounds the cells.

- Granulomas do not form in HIV infected peoples.
- Factors which contribute to growth of MAC
- High levels of triglycerides.
- Iron overload.
- Factors contributing to killing defect in advanced AIDS
- Absence of cytokine production.
- Impaired cell-mediated immunity.
- Impaired granuloma formation

Disseminated MAC

- All areas of the GIT are involved, most commonly the duodenum; the disease is usually patchy.
- If there is unimpeded replication massive thickening of the gut wall occurs. Which is the most likely reason for the abdominal pain found in this patient.
- Spread occurs to lymph nodes via local lymphatics.
- Bacterial replication occurs in lymph nodes and subsequent rupture may occur which results in haematogenous spread.
- Bacteria are taken up by phagocytic cells throughout the body and the reticuloendothelial system (liver, spleen & bone marrow).
- Genital ulcers
- CNS infection



In the absence of ARVs

- Disseminated multi-organ infection (early symptoms can be minimal).
- Features are:
 - Fever, night sweats, cachexia (major symptoms)
 - Diarrhoea, nausea
 - Abdominal pain
 - Intra-abdominal lymphadenopathy & hepatosplenomegaly
 - Anaemia (most likely anaemia of chronic disease).
 - Markedly elevated ALP with little elevation of transaminases or bilirubin.
 - Other manifestations – sinusitis, oral manifestations.
 - Respiratory symptoms are uncommon in children with dissemination and isolated pulmonary disease is rare.

Diagnosis

- Is made from isolation of the organism from blood specimens using Bactec or biopsy specimens of normally sterile sites.
- Multiple mycobacterial blood cultures may be required over a time frame due to fluctuating levels of bacteraemia.
- MAC in stool or sputum indicates colonization but not necessarily invasive disease.
- Histological features include:
 - Granulomas (necrotising & non-necrotising).

- Sheets of macrophages laden with AFB.
- Necrotising acute & chronic inflammation with histiocytes.
- Massive histiocyte infiltrate with intracellular AFB.

Conclusion

- MAC represents a late stage event in AIDS-related disease.
- Presentation may be localised or involve multiple organs.
- Disseminated disease remains a substantial cause of morbidity & mortality.
- ARV's & combination therapy- improve survival.
- Oral manifestations are rare.
- In this patient the oral lesion may be the primary manifestation of disseminated disease.
- Enlarged liver and abdominal pain may also be due to dissemination, biopsies will need to be done to confirm this.

Download images for this case



[Mycobacterium Avium Complex](#)

1 file(s) 957.22 KB

[Download](#)

Treatment

The patient was commenced on clarithromycin, ethambutol and ciprofloxacin.

After 5 weeks of MAC treatment [ARV's](#) were commenced; stavudine (d4T), lamivudine (3TC), efavirenz (Stocrin).

In view of the drug interactions known to occur between efavirenz and clarithromycin (effect of P450 metabolism) and the subsequent inadequate treatment of the MAC infection (positive MAC on TB Bactec after 2 months of treatment) azithromycin was commenced.

Download images for this case



[Mycobacterium Avium Complex](#)

1 file(s) 957.22 KB

[Download](#)

Final Outcome

- Gradually the child's appetite and weight improved.
- Viral load was suppressed
- CD4 count had increased to 1.08% (16cells/ul).
- A liver function test showed elevations in ALP, GGT, AST and ALT. This may be due to disseminated MAC however no liver biopsy was taken to confirm this.
- Hepatitis studies were negative.
- No further outcomes are yet available on this patient.

Download images for this case



[Mycobacterium Avium Complex](#)

1 file(s) 957.22 KB

[Download](#)

References

Greenspan D et al. (1997). Oral manifestations of HIV infection. *Aids Clinical Care*. 9:29-33.

[Link to Abstract](#)

Novak MJ. (1999) Necrotizing Ulcerative Peridontitis. *Annals of Peridontology*. 4:74-77.

[Link to Abstract](#)

Mayer DM. (2003) Noma: an “infectious” disease of unknown aetiology. *The Lancet*. 3:419-431.

[Link to Abstract](#)

Robinson P et al (1996). Oral Mycobacterium avium complex infection in a patient with HIV-related disease. *Oral Surg Oral Med Oral Pathol Oral Radiol Endod*. 81:177-179.

[Link to Abstract](#)

Volpe DDS et al. (1985) Oral manifestation of disseminated Mycobacterium avium intracellulare in a patient with AIDS. *Oral Surgery*. 60:567-570.

[Link to Abstract](#)

CDC. (2004) Mycobacterium avium Complex Disease. *MMWR*. 53:1-63.

[Link to Abstract](#)

Horsburgh CR. The pathophysiology of Disseminated Mycobacterium avium Complex Disease in AIDS. *The Journal of Infectious Diseases*. 1999;179(Suppl 3):S461-5

[Link to Abstract](#)

Download images for this case



[Mycobacterium Avium Complex](#)

1 file(s) 957.22 KB

[Download](#)

Evaluation – Questions & answers

What is the diagnosis

This is a severely immunosuppressed patient with HIV (WHO stage 4) disease complicated by disseminated MAC associated with erosion of the left side of the hard palate.

How does Mycobacterium Avium Complex predominantly enter the body?

Mycobacteria are environmental pathogens that predominantly enter the body through the gut via contaminated food or water. They can also enter the lungs by inhalation of liquid droplets containing mycobacteria.

Which cells are typically involved in mycobacterium infections?

Macrophages are the preferred target cells of mycobacteria. Transport through M cells deliver mycobacteria directly to macrophages in the Peyer's patches of the small intestine.

How do mycobacterium survive and spread throughout the body?

When Mycobacteria are phagocytosed by macrophages they are internalised into a membrane bound phagosome. The bacteria would then normally be destroyed by the fusion with a lysosome which contains degradative molecules. However Mycobacterium species have evolved mechanisms to prevent this fusion thus surviving and multiplying in the phagosome and spreading when the macrophages migrate to other tissues.

How is mycobacterium typically contained to prevent it from infecting the host?

This can only occur in immunocompetent hosts where prevention of mycobacterial spread is achieved by the formation of a granuloma. A granuloma sequesters infected macrophages in the centre, surrounded by immune cells which are predominantly CD4+ helper T lymphocytes. The fusion of infected macrophages

forms foamy macrophage giant cells most likely due to the release of mycolic acid products from the infected cells. A sheath of collagen fibres is also produced by fibroblasts which further surrounds the cells inside.

Will granulomas form in HIV infected patients?

No, granulomas do not form in HIV infected people.

Download images for this case



[Mycobacterium Avium Complex](#)

1 file(s) 957.22 KB

[Download](#)