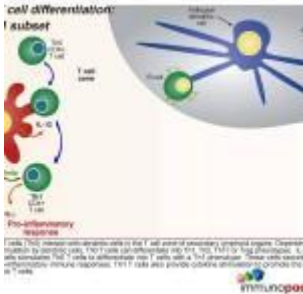


Case of a right axillary swelling



- [Patient presentation](#)
- [History](#)
- [Differential Diagnosis](#)
- [Examination](#)
- [Investigations](#)
- [Discussion](#)
- [Treatment](#)
- [Final outcome](#)
- [References](#)
- [Evaluation - Questions & answers](#)
- [MCQ](#)

Patient presentation

Four weeks after starting ARVs an 11 month old baby presented with a one-week history of a right axillary swelling which was found to be 2.5cm in diameter, hard, tender and non-fluctuant. Six days later the mass had enlarged to a size of approximately 4x3cm.

Acknowledgement

This case study was kindly provided by Dr Fatima Laher MBBCh, Dip HIV Man (SA) and Dr Gail Ashford MBBCh, DMH, Dip HIV Man (SA) from the Perinatal HIV research Unit, Chris Hani Baragwanath Hospital, Soweto. Additional input was also

provided by Dr Lucy Connell, Harriet Shezi Clinic, Chris Hani Baragwaneth Hospital, Soweto.

History

The child was born an HIV-exposed infant and received a single-dose of nevirapine syrup, as well as the standard immunisations including the Bacille Calmette-Guérin (BCG) vaccine. The mother was counseled and requested to bring the child back for an HIV test at 6 weeks. However this was not done until 9 months later at which time the infant tested HIV positive on two [rapid ELISA](#) blood tests with a CD4 percentage of 9.28 (absolute count $378 \times 10^6/L$). Her caregivers then defaulted on a referral and telephonic reminders to initiate her on [antiretroviral therapy](#).

One month later, the infant now 10 months old, presented with a two-week history of diarrhoea and a 4 month history of lethargy and failure to thrive. All immunisations were up to date and no TB contacts were identified. On examination she was found to be:

- Underweight (70% of expected weight for age)
- pale
- dehydrated
- shotty lymphadenopathy
- oral candidiasis
- bilateral otitis media
- hepatosplenomegally
- urinary tract infection

She was admitted to the paediatric ward where she was rehydrated, transfused with packed cells, and treated with analgesia, a topical antifungal and empiric intravenous antibiotics. Within 5 days her diarrhoea resolved completely and she was discharged on oral amoxicillin clavulanic acid and an appointment for the ARV clinic.

Two weeks later she was stable, having gained 1 kg. The mother still complained of persisting lethargy in the child. Examination revealed a non-tender hepatosplenomegaly and right-sided suppurative otitis media. She was started on ARVs stavudine, lamivudine and nevirapine.

Currently, four weeks after starting ARVs she presented with a one-week history of a right axillary swelling which was found to be 2.5 cm in diameter, hard, tender and non-fluctuant. It enlarged rapidly and within six days had reached approximately 4×3 cm.

Differential Diagnosis

- Pyogenic abscess
- Lymphoma
- Kaposi's sarcoma
- Immune Reconstitution Inflammatory Syndrome (IRIS)
- BCG adenitis
- Lymph node tuberculosis

Examination

[Weight on 10th centile](#)

Vitals

- Pulse-98
- Respiratory Rate-30
- Temperature-37.0
- Blood Pressure- not recorded

Head and Neck

- Oral thrush
- No cervical lymphadenopathy

Respiratory System

- Chest is symmetrical in appearance, no scars.
- Trachea in the midline
- Clear on auscultation bilaterally.

Cardiovascular System

- Capillary refill within 2 seconds.
- Normal S1 and S2, no gallop, no murmurs

Abdomen

- Mild hepatosplenomegaly.
- Bowel sounds present

Derm

- Round skin lesion on left arm

Investigations

	Values
White Cell Count	9.53x10 ⁹ /l
Haemoglobin	10.7 g/dl
Platelets	397x10 ⁹ /l
CD4	%=6.41, absolute count=77 cells/ul
Viral Load	<25 RNA copies/ml
Blood culture and Blood TB culture	Negative
Chest Radiograph	Normal
Tuberculin Skin Test	Negative
Gastric washing	AFB negative x3
Cerebrospinal fluid	Normal cells and chemistry, low adenosine deaminase
Bone marrow trephine and biopsy	Features in keeping with HIV

	Values
Ziehl-Nielsen Stain	Negative
TB culture	Negative

Histopathology Results:

Fine needle aspiration of Right Axillary Mass:

- Numerous lymphocytes, mature and immature, were seen, with several groups of epithelioid histiocytes and scattered Langerhans giant cells.
- A single Reed-Sternberg-like cell was noted.
- There were no features of lymphoma or any other malignant infiltrate.
- Scattered acid-fast bacilli were shown on Ziehl-Neelsen stain.

Histology of partial excision biopsy:

- Multiple lymph nodes with granulomatous non-caseating inflammation
- Langerhans type giant cells
- Epithelioid histiocytes
- No features of Hodgkin's Lymphoma, Kaposi's or any other malignant infiltrate

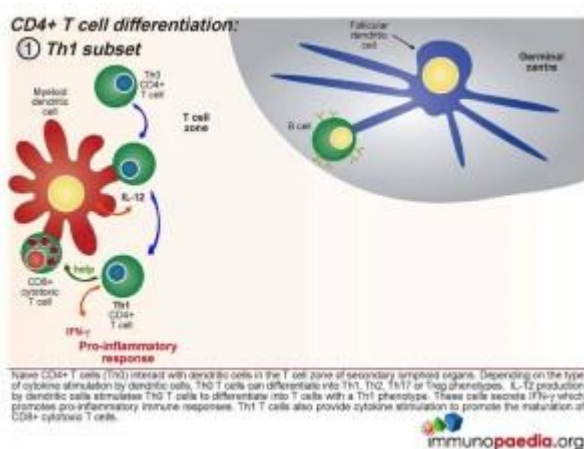
Discussion

Although the exact mechanism involved in the development of immune reconstitution inflammatory syndrome (IRIS) is not clearly understood, the explanation presented in this discussion is based on current theories.

As a background to understanding inflammatory responses, it is first important to appreciate that there are four defined CD4+ T cell subsets that provide a homeostatic balance between pro and anti inflammatory responses that occur in a healthy functioning immune system. [The four CD4+ T cell subsets](#) we

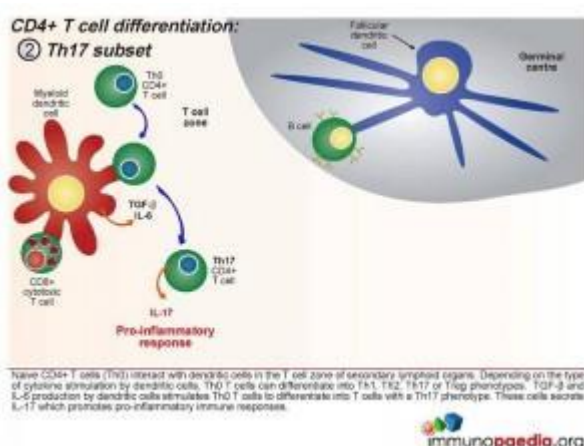
will discuss are the Th1, Th17, Treg and the Th2 subset.

Initially, naive CD4+ T cells (termed Th0) encounter processed antigen by dendritic cells through the MHC class II and T cell receptor in the T cell zone of secondary lymphoid tissues, such as the lymph nodes. Depending on the type of cytokine released by the dendritic cell upon this interaction, the Th0 CD4 cells differentiate into either Th1, Th2, Th17 or Treg phenotypes.



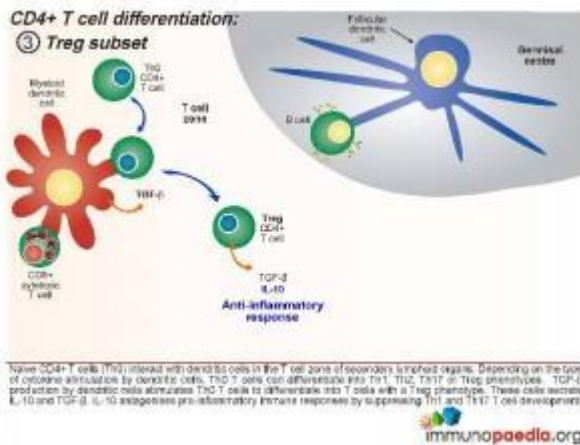
Th1 Subset

Interleukin-12 released by the dendritic cells will cause the Th0 CD4 cells to differentiate into Th1 functional cells. These cells secrete IFN-γ which promotes pro-inflammatory responses and will mobilize the maturation of CD8+ cytotoxic T cells and stimulate NK cells.



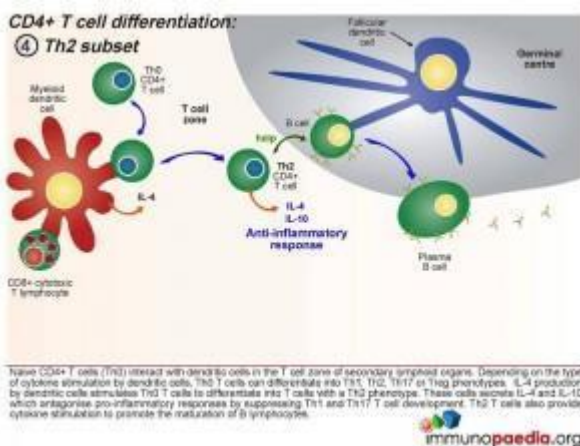
Th17 subset

When a combination of Transforming Growth Factor (TGF β) and IL-6 are released together by the dendritic cell, the Th0 CD4 cells differentiate into Th17 functional cells. These cells secrete IL-17, which also induces pro-inflammatory cytokines and tips the balance towards inflammatory immune responses.



Treg Subset

When the dendritic cells only release TGF- β , the Th0 CD4 cells differentiate into T regulatory (Treg) cells. These cells secrete IL-10 and TGF- β . IL-10 antagonises pro-inflammatory immune responses by suppressing Th1 and Th17 T cell development.

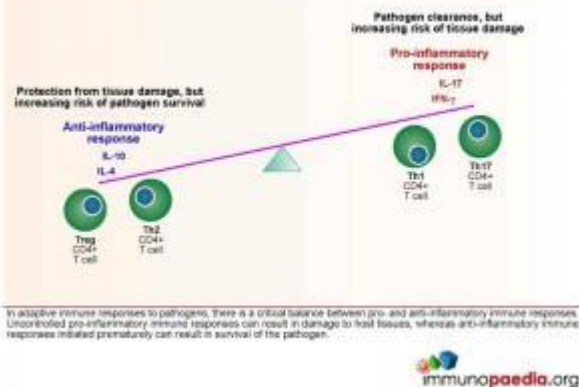


Th2 Subset

When the dendritic cells release IL-4 after Th0 binding, the

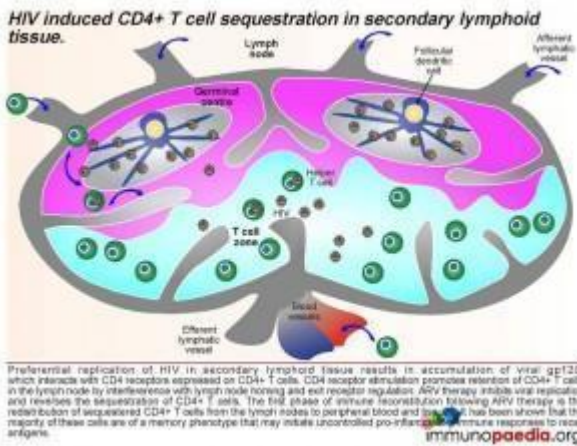
cells differentiate into Th2 cells. These cells secrete IL-4 and IL-10 which antagonise pro-inflammatory responses by suppressing Th1 and Th17 T cell development. Th2 T cells also provide cytokine stimulation to promote the maturation of B cells to plasma cells and the production of antibodies.

⑤ Balance of pro- and anti-inflammatory immune responses.



Homeostatic balance of pro- and anti-inflammatory immune responses.

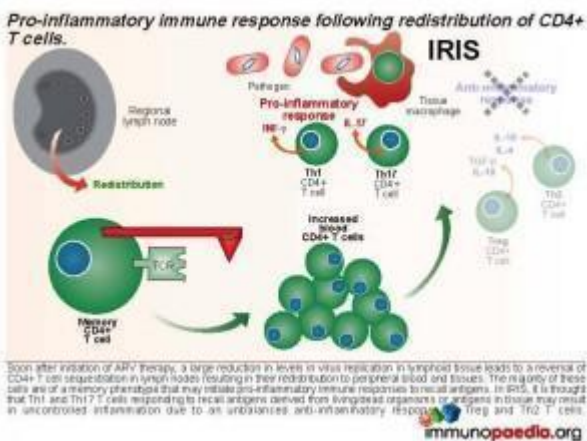
In adaptive immune responses to pathogens, there is a critical balance between pro- and anti-inflammatory immune responses. Uncontrolled pro-inflammatory immune responses can result in damage to host tissues, whereas anti-inflammatory immune responses initiated prematurely can result in survival of the pathogen, which is deleterious for the host. Th1 and Th17 CD4+ T cell subsets result in pro-inflammatory responses and Treg and Th2 CD4+ T cell subsets result in anti-inflammatory responses. It is thought that in a natural healthy immune response, there is a homeostatic balance between these subsets, resulting in the elimination of the pathogen, but also reducing the risk of tissue damage in the process. Inability to clear pathogen, or an overload of antigen, is either a result of this balance or a cause of an imbalance.



What happens when IRIS occurs?

Currently, it is thought that IRIS is a result of an imbalance towards pro-inflammatory immune responses during the immune reconstitution phase that occurs shortly after initiation of ARV therapy. There is a preferential differentiation of pro-inflammatory CD4+ T cell subsets.

If we break down the sequence of events: when a person becomes infected with HIV, the virus replicates preferentially in secondary lymphoid tissue.



This results in an accumulation of viral gp120, which interacts with CD4 receptors expressed on CD4+ T cells and promotes retention of CD4+ T cells in the lymph node by interference with lymph node homing and exit receptor regulation. When ARV therapy is initiated, the drugs

act by inhibiting viral replication and allow the release of sequestered CD4+ T cells. Thus, the first phase of immune reconstitution following ARV therapy is the redistribution of sequestered CD4+ T cells from the lymph nodes to peripheral blood and tissues. It has been shown that the majority of

these cells are Th1 and Th17 memory cells and the second phase is the resulting imbalance towards inflammatory responses due to these cells initiating uncontrolled pro-inflammation.

Download images for this case



[Immune Reconstitution Inflammatory Syndrome \(IRIS\)](#)

1 file(s) 881.71 KB

[Download](#)

Treatment

A course of amoxicillin clavulanic acid and metranidazole was prescribed for the differential of an abscess and clotrimazole for the skin lesion. Despite treatment, the right axillary mass continued to rapidly enlarge to a size of more than 10 cm.

Download images for this case



[Immune Reconstitution Inflammatory Syndrome \(IRIS\)](#)

1 file(s) 881.71 KB

[Download](#)

Final outcome

- Mycobacterium bovis was eventually cultured from the fine needle aspiration.

- Anti [TB treatment](#) was started.
- Nevirapine was switched to efavirenz to prevent drug interactions – specifically hepatotoxicity

Download images for this case



[Immune Reconstitution Inflammatory Syndrome \(IRIS\)](#)

1 file(s) 881.71 KB

[Download](#)

References

Sun HY et al. (2009). Immune reconstitution inflammatory syndrome in non-HIV immunocompromised patients. *Curr Opin Infect Dis.* Aug;22(4):394-402. Review.

[Link to Abstract](#)

Elston JW et al. (2009) Immune reconstitution inflammatory syndrome. *Int J STD AIDS.* Apr;20(4):221-4. Review.

[Link to Abstract](#)

Mori S et al. (2009). A brief review of potential mechanisms of immune reconstitution inflammatory syndrome in HIV following antiretroviral therapy. *Int J STD AIDS.* Jul;20(7):447-52. Review.

[Link to Abstract](#)

Download images for this case



Immune Reconstitution Inflammatory Syndrome (IRIS)

1 file(s) 881.71 KB

[Download](#)

Evaluation – Questions & answers

What is the diagnosis in this case?

BCG Adenitis Immune Reconstitution Inflammatory Syndrome (regional disease). Immune Reconstitution Inflammatory Syndrome (IRIS), or Immune Reconstitution Disease (IRD), is defined as paradoxical clinical deterioration (despite decreasing viral load and rising CD4 count) after starting HAART. It results from the interaction between an improving immune system and organisms that colonized the body during earlier stages of HIV infection. Clinical presentations vary depending on the causative organism and the organ system that is colonized.

In this specific case presentation, there was an acute lymphadenopathy ipsilateral to the BCG inoculation site occurring 4 weeks after initiation of HAART, which is fairly typical of BCG IRIS. In children, IRIS resulting from BCG may occur months to years after vaccination. Most occur within the first 3 months of starting HAART and can be as early as 1 week after initiation of HAART. Less commonly, IRIS can manifest as an occurrence of non-infectious disease, such as Guillain-Barré syndrome.

What is immune reconstitution inflammatory syndrome (IRIS)?

A paradoxical deterioration in a patient's condition after starting HAART – related either to a previously undetected infection or a partially treated infection. In the case of TB and BCG, restoration of cellular immunity to mycobacterial antigens is responsible for an inflammatory response with the lymphadenitis, fever, malaise. Less commonly, IRIS can manifest as an occurrence of noninfectious disease, such as Guillain-Barré syndrome.

What factors make a patient more likely to develop an IRIS event?

A patient with Stage IV immunosuppression and a low CD4 count is at a higher risk for an IRIS event. A CD4 <10% or <50 cells/ul is an independent risk factor of IRIS development. Patients who have been on TB treatment for a short period of time (less than 2 months) are more likely to develop an IRIS response to the dead/partially treated bacilli. Patients with suspicion of TB but not started on TB treatment before HAART are at higher risk for an 'unmasking of TB'.

In what time frame does an IRIS event occur?

Most IRIS events occur within the first 3 months of starting HAART

How does IRIS occur?

Although the exact method is not yet known it is thought that IRIS is due to an imbalance towards pro-inflammatory immune responses during the immune reconstitution phase that occurs shortly after initiation of ARV therapy. With a preferential differentiation of pro-inflammatory CD4+ T cell phenotypes.

Who should get BCG vaccinations?

The World Health Organization currently recommends giving BCG to all neonates in areas with a high prevalence of tuberculosis, irrespective of HIV exposure, unless the child has symptomatic HIV disease. HIV-infected infants and other immunodeficient infants are at risk of BCG-related complications. While disseminated disease is rare in immunocompetent children, HIV-infected children have significantly increased risk of developing distant or disseminated BCG disease.

BCG is on the current South African EPI and is given at birth

Should antiretroviral therapy be stopped or continued if IRIS is suspected/confirmed?

Ideally, HAART should be continued rather than risk the interruption of treatment. The IRIS event is occurring as a result of an infection other than HIV, and thus, the cause of the IRIS needs to be treated while HAART is continued. Mild

cases of IRIS can be treated supportively, while HAART is continued. In moderate cases of IRIS, physicians can consider the addition of temporary corticosteroids to dampen the inflammatory response while continuing HAART and the causative treatment. However, if the case is life threatening, then an interruption of HAART may be unavoidable and safer.

Should the patient be treated for TB?

Tuberculosis is highly endemic in South Africa and the possibility of dual disease with *M. bovis* BCG and *M. tuberculosis* should always be considered. Unless tuberculosis can be confidently excluded, pyrazinamide 20–25mg/kg/day should be included in the chemotherapeutic regimen for the first two months. This patient was not initially treated for tuberculosis (pyrazinamide excluded) in the light of her negative contact history, normal chest radiograph findings and her robust clinical response to HAART.

Should her ARV's be stopped in the face of rapidly enlarging lymphadenopathy?

IRIS occurs because there is a robust immune response to appropriate HAART. Treatment is directed towards the pathogen provoking the exuberant inflammatory response. HAART should be continued with supportive treatment as necessary. With severe reactions, the addition of temporary corticosteroids to dampen the inflammatory response may be considered. Corticosteroids would be indicated when there is threatened airway obstruction, rapidly enlarging cervical or hilar lymph nodes or abdominal obstruction secondary to enlarging intra-abdominal lymph nodes. However, if the case is life threatening, an interruption of HAART may be unavoidable and safer.

Who is at risk of an IRIS reaction?

WHO Stage IV disease and a low CD4 (especially CD4 <10% or <50 cells/ μ l) are risk factors for IRIS development as well as patients starting ART in close proximity with diagnosis of an opportunistic infection (OI). For example, children who start HAART within two months of starting tuberculosis treatment are more at risk of an IRIS reaction to the dead or dying tubercle bacilli.

Download images for this case



[Immune Reconstitution Inflammatory Syndrome \(IRIS\)](#)

1 file(s) 881.71 KB

[Download](#)

Multiple Choice Questions

**Earn 1 HPCSA or 0.25 SACNASP CPD Points
– [Online Quiz](#)**

Download images for this case



[Immune Reconstitution Inflammatory Syndrome \(IRIS\)](#)

1 file(s) 881.71 KB

[Download](#)