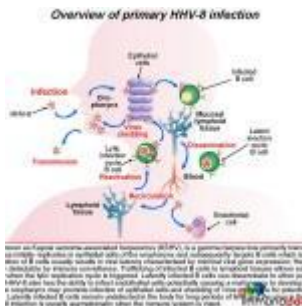


A case of cough, wasting and Lymphadenopathy



- [Patient Presentation](#)
- [History](#)
- [Differential Diagnosis](#)
- [Examination](#)
- [Investigation](#)
- [Discussion](#)
- [Treatment](#)
- [Final Outcome](#)
- [References](#)
- [Evaluation - Questions & answers](#)
- [MCQ](#)

Patient Presentation

A 32 year old female presented to the emergency room with a two month history of worsening dyspnea, cough with production of sputum, haemoptysis and extensive weight loss. At the time of presentation she was wasted and in moderate respiratory distress.

History

- Known RVD positive.
- Diagnosed three years previously but not on ARV's. Lost

to follow-up since initial diagnosis.

Past medical history

- RVD positive

Past surgical history

- Nil

Family history

- Nothing of significance

Allergies

- Nil known

Medication

- Nil

Social history

- 6 pack year history of smoking, stopped 3 years ago
- No ethanol use
- No recreational drugs

Differential Diagnosis

- Community acquired pneumonia
- TB
- Pneumocystis
- Kaposi Sarcoma

Examination

ON ADMISSION:

Appearance

- Awake and alert, ill-looking wasted female

Vitals

- Temperature: 38°C
- Blood pressure: 110/70
- Heart rate: 100
- Respiratory rate: 36 breaths per minute

General

- Conjunctival pallor
- Cervical, axillary and inguinal lymphadenopathy

ENT

- Raised purple nodule on palate, 4cm in length

Chest

- Crackles bilaterally

Abdomen

- Not distended
- Soft, no generalised tenderness
- No organomegally
- Bowel sounds present

Dermatological

- Two violaceous plaques, non tender, 2cm in diameter on the upper back.

On Admission:

		Reference Ranges
WCC	5	4-12x10 ⁹ /L
HB	8.5	12.1-15.2g/L
Platelets	138	140-450x10 ⁹ /L

		Reference Ranges
CD4+	35 cells/mm ³	
Arterial Blood Gas		
pH	7.4	7.35 - 7.45
PCO ₂	33.8 mmHg	35-45 mmHg
PO ₂	52.2 mmHg	80 - 100 mm Hg
O ₂ sats	89.3	

Chest X ray:

- Diffuse reticular nodular infiltrate
- Peri-hilar interstitial infiltrates bilaterally
- Left sided pleural effusion

CT Chest:

- Peri-bronchovascular interstitial thickening
- Multiple small nodules in parenchyma of both lungs
- Thickening of interlobular septa
- Hilar lymphadenopathy
- Small left pleural effusion

Sputum smears:

- TB negative X3

Biopsy of lesion on palate

- *Macroscopic:* Specimen consists of a nodular fragment of mucosa-covered tissue with a blue appearance, measuring 11 x 6 x 4mm
- *Microscopic:* fragments of squamous mucosa covered tissue showing ectatic, slit-like vascular spaces surrounded by a spindle cell proliferation admixed with plasma cells and extravasated red blood cells. Scattered neutrophils are also seen and hyaline globules are present. The overlying mucosa is reactive.

Features are consistent with Kaposi sarcoma.

Immunohistochemistry:

- HHV8-positive, nuclear dot-like staining.

Open lung biopsy:

- Typical histologic findings of Kaposi sarcoma (as described above)- indicating Pulmonary Kaposi Sarcoma (KS)

Discussion

Introduction

This patient was diagnosed with Kaposi's sarcoma (KS), which is a spindle cell, angioproliferative, tumour-like lesion that typically develops in the skin, eventually disseminating to multiple cutaneous sites, viscera and lymph nodes. Initially a rare disease, it has increased in prevalence globally because of its association with HIV. In this discussion, we will outline the types of KS, the intrinsic association with human herpes virus type 8 and the immunology behind the development of lesions.

Four clinically relevant and different types of KS have been identified:

1. Classical or sporadic KS, originally described as an indolent tumor in the extremities of elderly males of eastern and Mediterranean Europe.
2. Endemic KS, predominant in eastern and central sub-Saharan Africa before the AIDS epidemic and clinically similar to Classical KS, but also seen in a more fulminant and fatal form in children.
3. AIDS associated KS, the most frequent tumor of HIV-I infection and the most aggressive and rapidly growing form of KS, with early dissemination to the skin and viscera.
4. Iatrogenic KS, seen in drug related immunosuppressed

patients, e.g. transplant patients.

In spite of the clear clinical differences, all forms of KS are associated with human herpes virus type 8 (HHV-8) also known as Kaposi sarcoma-associated herpesvirus (KSHV). Other diseases associated with KSHV include primary effusion lymphoma or body-cavity-based-lymphoma (PEL/BCBL) found in AIDS patients and Multicentric Castleman's disease (not discussed here).

This discussion will look at KSHV in immunocompetent patients and in the setting of immunocompromised patients, such as people with HIV, which is likely occurring in our patient. We will also explore the adaptations that make this virus so efficient in circumventing the immune system. Lastly we will discuss the infection of endothelial cells, with their subsequent transformation and proliferation into spindle cells and the development of KS lesions.

Signs and symptoms of Kaposi Sarcoma

Lesions in KS may involve the skin, oral mucosa, lymph nodes, and visceral organs. Most patients present with cutaneous disease. Visceral disease may occasionally precede cutaneous manifestations.

Cutaneous lesions in Kaposi sarcoma are characterized as follows:

- Cutaneous lesions may occur at any location but are usually found on the lower extremities and the head and neck region
- Lesions may have macular, papular, nodular, or plaquelike appearances
- Nearly all lesions are palpable and nonpruritic
- Lesions may range in size from several millimeters to several centimeters in diameter
- Lesions may assume a brown, pink, red, or violaceous color and may be difficult to distinguish in dark-

skinned individuals

- Lesions may be discrete or confluent and typically appear in a linear, symmetrical distribution.
- Mucous membrane involvement is common (palate, gingiva, conjunctiva)

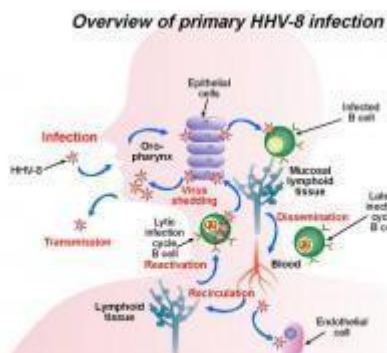
Visceral KS:

KS lesions may also develop in internal organs such as lung and GIT. This disseminated disease is associated with a greater degree of immunosuppression. Signs and symptoms of GIT involvement can include the following:

- Odynophagia, dysphagia
- Nausea, vomiting, abdominal pain
- Hematemesis, hematochezia, melena
- Bowel obstruction

Pulmonary lesions are usually associated with advanced immune-suppression and although they may occasionally be an asymptomatic radiographic finding, it is usually associated with evidence of respiratory disease, including:

- Cough
- Dyspnea
- Hemoptysis
- Respiratory failure



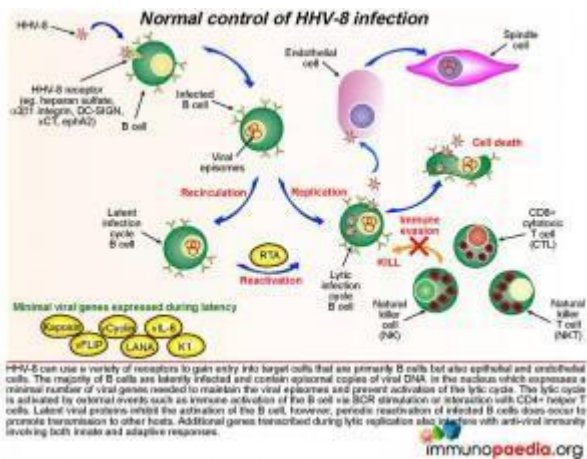
HHV-8, also known as Kaposi sarcoma-associated herpesvirus (KSHV), is a gamma herpesvirus primarily transmitted through saliva. The virus initially replicates in epithelial cells of the oropharynx and subsequently targets B cells which is a primary viral reservoir. Infection of B cells usually results in viral latency characterized by minimal viral gene expression. Hence these cells are not readily detectable by immune surveillance. Trafficking of infected B cells to lymphoid tissues allows additional B cells to be infected when the lytic replication cycle is triggered. Latently infected B cells can disseminate to other parts of the body via the blood. HHV-8 also has the ability to infect endothelial cells potentially causing a malignancy to develop. Lytic infection of B cells in the oropharynx may promote infection of epithelial cells and shedding of virus into saliva for potential transmission to other hosts. Latently infected B cells remain undetected in the body for long periods of time. www.immunopedia.org

Overview of primary Human Herpes Virus type 8 (HHV-8)

infection

To better understand HHV-8 infection we need to first look at how humans become infected with the virus and the viral replication cycle in the cell. HHV-8 or KSHV is a gamma herpesvirus which is primarily transmitted through saliva. Following infection, the virus establishes a life-long persistent infection in the new host as a result of multiple immune evasion mechanisms. The virus initially replicates in epithelial cells and B cells of the oropharynx and subsequently targets B cells, the primary viral reservoir. Infection by HHV8 results in one of two infection states in the cell. This is depicted in graphic 1. In lytic infection, many viral genes are expressed, the cell makes new virus particles and it dies after a short time period. In latent infection, only a few viral genes are expressed. This limited gene expression enables the infected cell to escape immune surveillance and survive long term.

Latently infected B cells then travel to different areas around the body. Those that traffic to lymphoid tissues may be triggered into the lytic replication cycle by various signals such as inflammation. Lytically infected B cells are thought to promote infection of other cell types such as endothelial cells. Infected hosts will typically remain asymptomatic provided their immune system is intact, but may shed virus asymptotically in saliva from time to time. In our case study, the patient has an immunocompromised immune system, due to HIV infection, and thus her ability to control HHV-8 is poor. HHV-8 infection of endothelial cells is necessary for the development of Kaposi sarcoma.

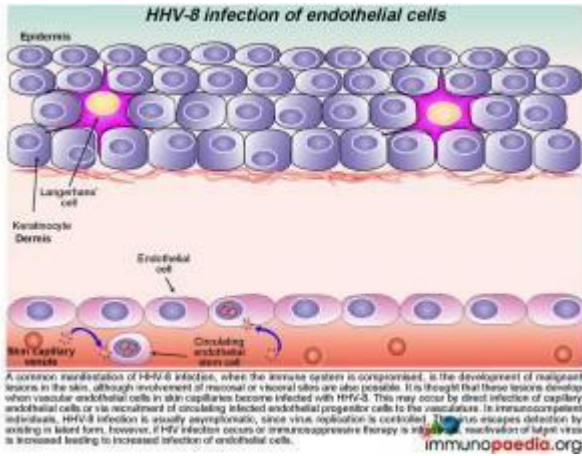


Normal immune control of HHV-8 infection

HHV-8 can use alternative receptors, including heparin sulphate, $\alpha 3 \beta 1$ integrin and [DC-SIGN](#), to gain entry into target cells. As described, the target cells are primarily B cells but the virus can also infect epithelial and endothelial cells. Once infected, most B cells are latently infected, containing episomal copies of viral DNA which expresses a minimal set of viral genes needed to maintain the viral episomes and prevent activation of the lytic cycle. These minimal viral genes are depicted in graphic 2 as Kaposin, vFLIP, vCyclin, LANA, vIL-6 and K1.

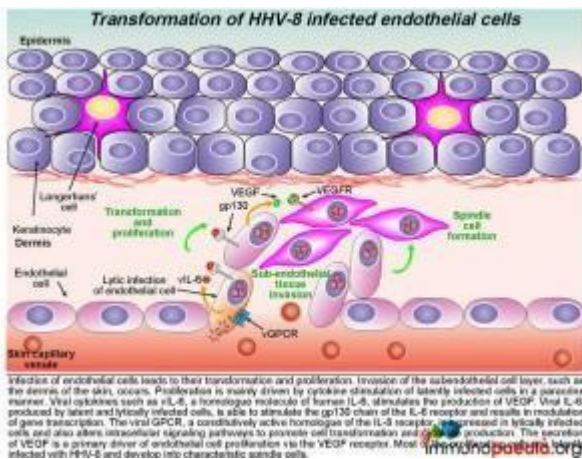
The lytic cycle may be activated by external events such as immune activation of the B cell via B cell receptor (BCR) stimulation or interaction with CD4+ helper T cells. Latent viral proteins normally inhibit the activation of infected B cells. Viral genes transcribed during both latent and lytic replication cycles subvert innate and adaptive anti-viral immune responses. HHV-8 infection of vascular endothelial cells transforms them and causes them to adopt a spindle cell morphology (through the action of latency associated genes). These spindle cells produce cytokines which cause them to proliferate and under normal conditions this proliferation is well controlled.

The process of infection of endothelial cells in an immunocompromised host will be described in the next slides



HHV-8 infection of endothelial cells

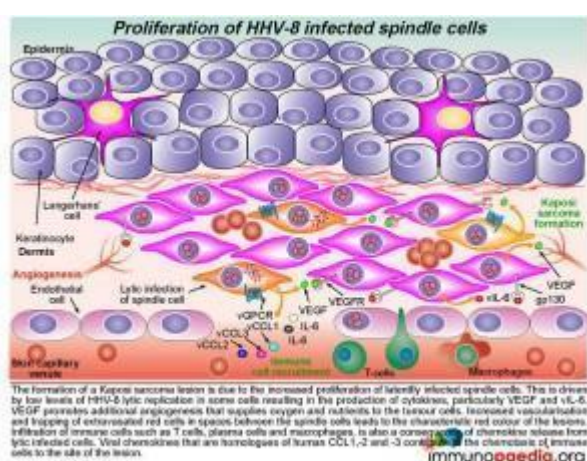
When the immune system is compromised a common manifestation of HHV-8 infection is the development of malignant lesions in the skin, although involvement of mucosal or visceral sites are also possible. It is thought that these lesions develop when vascular endothelial cells in skin capillaries become infected with HHV-8. Which occurs by direct infection of capillary endothelial cells or via circulating infected endothelial progenitor cells. In immunocompetent individuals, HHV-8 infection remains asymptomatic because viral replication is controlled and existing virus escapes detection by remaining in latent form. However, if HIV infection occurs or immunosuppressive therapy is introduced, reactivation of latent virus is increased leading to increased infection of endothelial cells.



Transformation of HHV-8 infected endothelial cells

Infection of endothelial cells leads to their transformation and proliferation by virus encoded gene products. Invasion of the subendothelial cell layer, such as the dermis of the skin, occurs. Proliferation of spindle cells is mainly driven by cytokine stimulation. Viral cytokines produced by virus-infected cells such as viral (v) IL-6, a homologue molecule of human [IL-6](#), stimulates the production of vascular endothelial growth factor ([VEGF](#)). Viral IL-6, is able to bind to the [gp130](#) chain of the human [IL-6 receptor](#), but does not need to bind the co-receptor to exert its activity. Because of this the vIL-6 acts on a wider range of target cells (although it is intrinsically less active than the human protein).

The virus also expresses a constitutively active homologue of the [IL-8](#) receptor, known as viral GPCR, which is a key protein in the KS disease process. It is expressed in lytically infected cells. It activates intracellular signaling pathways (in the same cell expressing it) to induce production of a battery of cytokines including: IL-8, IL-6, [IL-1b](#), [TNFa](#), [bFGF](#) and VEGF. The secretion of VEGF is a primary driver of endothelial cell proliferation via the VEGF receptor. Most of the proliferating cells are latently infected with HHV-8 and develop into characteristic spindle cells.



Formation of a Kaposi Sarcoma lesion

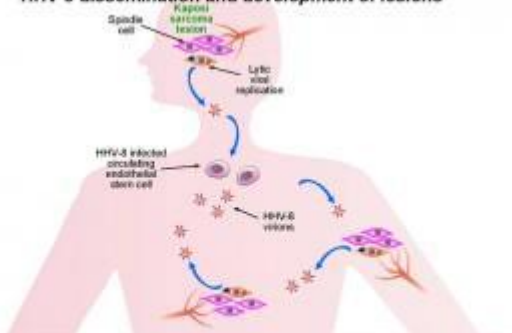
The formation of a KS lesion is due to the increased proliferation of latently infected spindle cells. This is

driven by low numbers of HHV-8 infected cells that are in the lytic phase. The cytokines produced by these cells, particularly VEGF and vIL-6 drive the other spindle cells to proliferate (by para-crine oncogenesis). VEGF promotes additional angiogenesis that supplies oxygen and nutrients to the tumour cells. Increased vascularisation and trapping of extravasated red cells in spaces between the spindle cells leads to the characteristic red colour of the lesions. Infiltration of immune cells such as T cells, plasma cells and macrophages, is also a consequence of chemokine release from lytic infected cells. Viral chemokines that are homologues of human [CCL1](#), [CCL2](#) and [CCL3](#) contribute to the chemotaxis of immune cells to the site of the lesion.

A feature of the formation of KS lesions is Paracrine neoplasia:

KS is not a mono-clonal malignancy. Rather, it is the result of polyclonal proliferation of virus infected spindle cells. This process is driven by viral genes, most of which are expressed in lytically infected cells. In an early KS lesion, most of the proliferating spindle cells are latently infected. Occasional lytically infected cells secrete key cytokines that act in a para-crine fashion to drive the surrounding cells to proliferate further, recruit inflammatory cells to the lesion and induce angiogenesis.

HHV-8 dissemination and development of lesions



Kaposi sarcoma lesions develop in the skin at late stages of HHV-8 reactivation following a failure of the immune system to control virus replication. Dissemination of virus produced by increased lytic replication promotes the development of additional lesions which may also be due to increased selection of circulating endothelial stem cells. Malignancies can also develop at mucosal sites or in other organs. Spindle cells do not appear to metastasise to other sites, rather new lesions develop following free virus infections of endothelial cells or recruitment of infected endothelial cells to the vasculature.

HHV-8 dissemination and development of cutaneous lesions

Kaposi sarcoma lesions develop in the skin at late stages of

HHV-8 reactivation, following failure of the immune system to control virus replication. Widespread dissemination to the viscera and mucosa may also occur. Thus when our patient was diagnosed with pulmonary KS, it was indicative of systemic disease and explained her symptoms such as fever, drenching night sweats and weight loss. These cytokine driven responses are always a poor prognostic sign.

Download images for this case



[HHV-8 Kaposi Sarcoma](#)

1 file(s) 2.29 MB

[Download](#)

Treatment

- Following admission this patient was started on empiric TB therapy.
- First-line ARVs were initiated – 3TC, Tenofovir and efavirenz. (If a patient has non visceral disease HAART may be tried as the sole treatment).
- Due to the presence of visceral disease this patient was also referred for chemotherapy: [vincristine](#), [doxorubicin](#) and bleomycin.

Although local therapy was not administered to this patient, the following local therapies can be used for locally advanced disease of in patients with cosmetically unacceptable lesions, including:

- Radiation therapy

- Cryotherapy
- Laser therapy
- Surgical excision
- Intralesional vinca alkaloid therapy
- Topical retinoids

Download images for this case



[HHV-8 Kaposi Sarcoma](#)

1 file(s) 2.29 MB

[Download](#)

Final Outcome

The patient experienced a severe episode of haemoptysis, and died from uncontrolled pulmonary haemorrhage.

Pulmonary involvement is the most common cause of mortality in these patients.

Download images for this case



[HHV-8 Kaposi Sarcoma](#)

1 file(s) 2.29 MB

[Download](#)

References

Pyakurel P et al (2007). KSHV/HHV-8 and HIV infection in Kaposi's sarcoma development. Infect Agent Cancer. Feb 2;2:4.

[Link to abstract](#)

Sathish N et al (2011) Evasion and subversion of interferon-mediated antiviral immunity by Kaposi's sarcoma-associated herpesvirus: an overview., J Virol. Nov;85(21):10934-44.

[Link to abstract](#)

Dittmer DP et al (2013) Kaposi sarcoma associated herpesvirus pathogenesis (KSHV)-an update., Curr Opin Virol. Jun;3(3):238-44.

[Link to abstract](#)

Ruocco E et al (2013). Kaposi's sarcoma: Etiology and pathogenesis, inducing factors, causal associations, and treatments: Facts and controversies., Clin Dermatol. Jul-Aug;31(4):413-22

[Link to abstract](#)

Mesri EA et al (2010) Kaposi's sarcoma and its associated herpesvirus., Nat Rev Cancer. Oct;10(10):707-19.

[Link to abstract](#)

Dimaio TA et al (2012) KSHV Induction of Angiogenic and Lymphangiogenic Phenotypes., Front Microbiol. Mar 30;3:102

[Link to abstract](#)

Montaner S et al (2013) Molecular mechanisms deployed by virally encoded G protein-coupled receptors in human diseases., Annu Rev Pharmacol Toxicol. 53:331-54

[Link to abstract](#)

Download images for this case



HHV-8 Kaposi Sarcoma

1 file(s) 2.29 MB

[Download](#)

Evaluation – Questions & answers

What is the diagnosis?

Pulmonary Kaposi Sarcoma

What is the causative organism associated with Kaposi sarcoma?

Human Herpes Virus- 8 (HHV-8)

What are the target cells for this infection?

Primarily B cells, also epithelial and endothelial cells.

In what two forms does the virus exist?

Latent phase and a lytic phase

What is the benefit of viral latency?

This phase is characterised by minimal viral gene expression. Therefore the infected cells are not readily detected by immune surveillance, allowing the virus to exist undetected in the host.

What is the benefit of the lytic phase?

In the oropharynx this promotes infection of epithelial cells and shedding of virus into the saliva for transmission to other hosts.

How do Kaposi Sarcoma lesions form?

When the immune system is compromised HHV-8 infection of vascular endothelial cells in skin capillaries occurs which leads to their transformation and proliferation. Proliferation is mainly driven by cytokine stimulation of these latently infected cells which develop into characteristic spindle cells and the formation of a KS lesion.

Why are Kaposi Sarcoma lesions red in colour?

These are vascular lesions, due to angiogenesis from cytokines such as VEGF. The increased vascularisation and trapping of extravasated red cells in spaces between the spindle cells leads to the characteristic red colour of the lesions.

What is a poor prognostic sign of KS?

Visceral involvement with constitutional symptoms.

Download images for this case



[HHV-8 Kaposi Sarcoma](#)

1 file(s) 2.29 MB

[Download](#)

Multiple Choice Questions

Earn 1 HPCSA or 0.25 SACNASP CPD Points
– [Online Quiz](#)

Download images for this case



[HHV-8 Kaposi Sarcoma](#)

1 file(s) 2.29 MB

[Download](#)