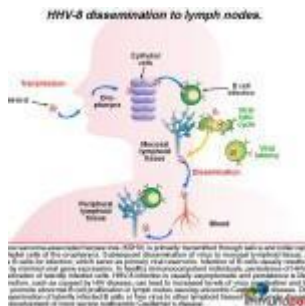


# A case of Lymphadenopathy and night sweats



- [Patient Presentation](#)
- [History](#)
- [Differential Diagnosis](#)
- [Examination](#)
- [Investigations](#)
- [Discussion](#)
- [Treatment](#)
- [Final Outcome](#)
- [References](#)
- [Evaluation - Questions & answers](#)
- [MCQ](#)

## Patient Presentation

A 33 year old male presents with a one month history of a non-productive cough, fever, night sweats, malaise, abdominal pain and weight loss.

## History

- Known HIV positive
- Diagnosed 8 months previously but not on ARV's.

## Past medical history

- Nothing of significance

### **Past surgical history**

- Nil

### **Family History**

- Mother has hypertension, on medication
- Father is asthmatic, on medication

### **Allergies**

- Nil known

### **Medication**

- Nil

### **Social history**

- 10 pack year history of smoking, stopped two years ago
- Occasional ethanol use
- No recreational drugs

## **Differential Diagnosis**

- TB
- Lymphoma
- Pulmonary KS
- Sepsis
- Opportunistic infection
- Multicentric castlemans disease (MCD)

## **Examination**

### **Examination on admission**

#### **Appearance**

- Awake and alert, ill looking wasted man

## Vitals

- Temperature: 38C
- BP:90/65
- HR:85
- RR:20 breaths per minute

## General

- Moderate conjunctival pallor
- Ankle oedema
- Generalised lymphadenopathy (LAD), with one large node (3x3cm) in the right supraclavicular region

## Respiratory system

- Tachypnoea with respiratory rate of 20 breaths per minute
- Crackles bilaterally

## Abdomen

- Not distended
- Mild generalised tenderness on palpation
- Slight hepatomegaly and large, easily palpable splenomegaly
- No other masses
- Bowel sounds present

## Cardiovascular

- Normotensive
- No murmurs or added heart sounds

## CNS

- Normal level of consciousness, alert and co-operative
- Gait, power, tone, sensation and reflexes intact and functioning within normal limits.

## Dermatological

- An erythematous, maculopapular, nonpruritic rash on the upper limbs and trunk. No confluence between lesions.

## Investigations

Investigations	Results	Reference ranges
WCC	3.74	4-12x10 <sup>9</sup> /L
RCC	2.58	4.5-5.5x10 <sup>12</sup> /L
HB	8	12.1-15.2g/L
MCV	86.2fl	79.1-98.9
MCH	30.2pg	27.0-32.0
MCHC	32.1g/dL	32.0-36.0
Red cell distribution width	12.7	11.6-14.0x10 <sup>9</sup> /L
Platelets	219	140-450x10 <sup>9</sup> /L
Normocytic normochromic anaemia		
CD4+	236 cells/mm <sup>3</sup>	
CRP	150mg/L	0.0-5.0
LFT		
Total Protein	72g/L	60-85
Albumin	27g/L	35-52
GGT	53U/L	0-35
ALT	85U/L	14732
AST	70U/L	14732
LDH	1280U/L	248-480
Sputum	AFB negative x3	
Urine dipstix	++ protein	

### Chest X ray:

- Lung fields clear

- Small bilateral pleural effusions

### **CT Abdomen:**

- Confirms clinical findings.
- Enlarged spleen, slightly enlarged liver, intra-abdominal and retroperitoneal LAD

### **Lymph node excision biopsy:**

- Histology shows angio-follicular hyperplasia, with hyperplastic follicles surrounded by a concentric mantle of plasma cells.
- Histology was compatible with multicentric castlemans disease (MCD), plasma cell variant.
- Follicle surrounded by a broad mantle zone consisting of a concentric layering of lymphocytes resulting in an onion-skin appearance. The follicles are frequently penetrated radially by a sclerotic blood vessel.

### **Immunohistochemistry:**

- Multiple plasma cells positive for HHV8 LANA-1 protein (this test is used to show if virus is present)
- Plasma HHV8 viral load 10 000 copies/ ml

## **Discussion**

Our case focuses on a 33 year old HIV positive man not on ARV treatment, who presents with a one month history of constitutional symptoms and a generalized lymphadenopathy. A lymph node biopsy is taken, which reveals hyperplastic follicles surrounded by a concentric mantle of plasma cells – consistent with a diagnosis of multicentric Castleman's disease. Our discussion will begin with an introduction to this rare disease and will follow with the the immunology behind its dissemination and progression.

### **Introduction**

Castleman's disease is an uncommon lymphoproliferative disorder characterized by benign tumours that develop in the lymph nodes. Most often, they occur in the neck, chest and/or abdomen but may also be found in the axilla, pelvis, and pancreas. The disease is associated with human herpesvirus type-8 (HHV-8).

Castleman's disease is divided into four types, based on histology and location.

The first two are determined by the microscopic appearance of the lymph node:

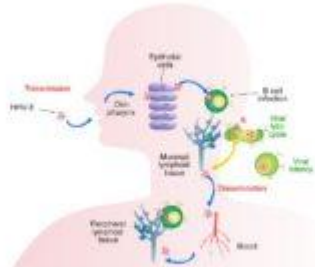
- hyaline-vascular type. More than 90 percent of the cases. Most individuals remain asymptomatic.
- plasma cell type. Associated with constitutional symptoms such as fever, weight loss, skin rash, early destruction of red blood cells with resulting haemolytic anaemia and increased immune factors resulting in hypergammaglobulinaemia.

The remaining two types are defined by the number of anatomic regions affected:

- Unicentric Castleman's disease affects lymph nodes in only one region
- Multicentric Castleman's disease affects multiple regions, including the liver and spleen with a resulting hepatosplenomegaly.

We describe a patient with a combination of these microscopic and anatomic variants.

**Initial transmission and dissemination of disease to the lymph nodes**



HHV-8 or Kaposi sarcoma-associated herpesvirus (KSHV) is primarily transmitted through saliva. Initial virus replication occurs in submandibular gland of the oropharynx, followed by dissemination of virus to mucosal lymphoid tissue, particularly the tonsils, where B cells are targeted, which serve as primary and reservoir infection. B cells usually reside in oral lesions characterized by increased gene expression, in healthy immunocompetent individuals. Viral persistence is facilitated by chronic reactivation of already infected cells. Infection is usually asymptomatic and persistence is lifelong. However, certain dysfunctions, such as HIV disease, increased levels of virus replication and high replication, conditions can promote chronic B cell proliferation, in lymph nodes causing unilocular Castleman's disease. Other oral lesions involve dissemination of latently infected B cells or free virus to other lymphoid tissues can produce disease at other sites leading to the development of virus disease multicentric Castleman's disease.

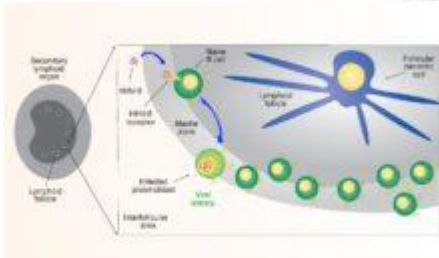
Human herpesvirus type-8 (HHV-8) or Kaposi sarcoma-associated herpes virus (KSHV) is primarily transmitted through saliva. The virus initially replicates in the epithelial cells lining the oropharynx and then disseminates

to local mucosal lymphoid tissue, in particular the tonsils. The virus targets B cells as its primary reservoir resulting in viral latency with minimal viral gene expression.

When the host is healthy with intact immune function, persistence of HHV-8 is facilitated by chronic reactivation of **latently** infected cells. Resulting infection is typically asymptomatic and viral persistence is life long. However, in people who are immunodeficient, such as in individuals who are HIV positive, their immune dysfunction can lead to increased levels of HHV-8 reactivation and **lytic** replication.

Release of cytokines can promote abnormal B cell proliferation in lymph nodes with a localized distribution, known as unicentric Castleman's disease. Increased virus replication, as a result of loss of immune control, can lead to the dissemination of latently infected B cells or free virus that infect multiple lymph node sites resulting in multicentric Castleman's disease.

In order to better understand how viral latency is established we need to look in greater detail at the infection of naïve B cells and how they bypass the germinal centers of secondary lymphoid organs.

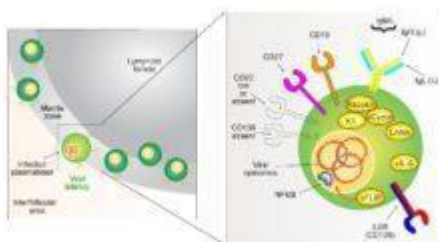


Infected naïve B cells in lymphoid tissue leads to viral latency by default. Infected B cells can transform and secrete plasmablasts. HHV-8 virus encodes membrane receptors to gain entry into susceptible cells (e.g. heparan sulfate, α3β1 integrin, DC-SIGN, xCT and ephA2) which facilitates internalisation of virus in endosomes. Latent infection is characterised by maintenance of viral episomes in the nucleus and expression of a minimal number of viral genes which promote long term survival of infected cells, as well as evade host immune surveillance. Viral gene products are thought to transform naïve B cells by mediating intracellular signalling events normally associated with germinal centre reactions. Infected naïve B cells bypass germinal centre and localize to the marginal zone of lymphoid tissues. Plasmablasts are characterized by size and express cytoplasmic and membrane-bound immunoglobulins exclusively composed of IgM isotypes and lambda light chains.

Viral infection of naïve B cells in lymphoid tissue leads to viral latency. These infected B cells are transformed and resemble plasmablasts, but do not secrete immunoglobulins. HHV-8 uses several membrane

receptors to gain entry into susceptible target cells including heparan sulfate, α3β1 integrin, [DC-SIGN](#), [xCT](#) and [ephA2](#). These receptors facilitate internalisation of the virus via endocytosis. Latent infection is characterised by maintenance of viral episomes in the nucleus and expression of a minimal number of viral genes which promotes long term survival of infected cells and escape from immune surveillance. Viral latent gene products are thought to transform naïve B cells by mediating intracellular signaling events normally associated with germinal centre reactions. However, the virus infected naïve B cells actually bypasses the germinal centre and localizes to the marginal zone of lymphoid follicles.

The infected plasmablasts located in the mantle zone are characteristically large in size and express cytoplasmic and membrane-bound immunoglobulins exclusively composed of IgM isotypes and lambda light chains. The characteristics of these plasmablasts and their resulting pathology are described in greater detail in the next two graphics.



HHV-8 latency in B cells is associated with expression of six viral proteins. The viral protein pLRF is thought to mediate transformation of infected B cells into plasmablasts via translocation of genes under the control of the transactivator factor. pLRF also facilitates expression of viral genes as well as production of B cell growth factors to the long term survival of infected B cells. A number of cell surface alterations characterize the phenotype of infected plasmablasts. It such as CD138, a plasma cell marker and membrane bound immunoglobulin B cell marker is evident as well as expression of the B cell marker CD27 and CD226 (a memory marker). Membrane bound immunoglobulins that are exclusively IgM, are also hallmarks of HHV-8 infection. In normal B cell development, B cells down expression of lambda light chains following successful B cell class switch recombination and class switch recombination. Plasmablasts (due to successful germinal centre reaction)

**HHV-8 infected plasmablasts express particular membrane markers**

HHV-8 latency in B cells is associated with expression of six viral proteins (Kaposin, K1, vCyclin, LANA, vIL-6, vFLIP). The

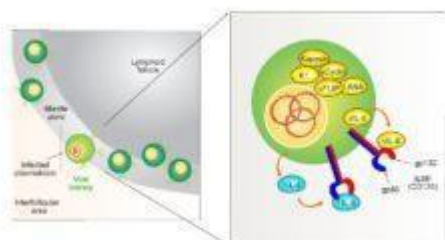


viral protein vFLIP, is thought to mediate transformation of infected B cells into plasmablasts via expression of genes under the control of the host transcription factor NF- $\kappa$ B. Expression of anti-apoptotic genes as well as production of B cell growth factors (under the control of NF- $\kappa$ B) leads to the long term survival of latently infected B cells. A number of cell surface alterations characterize the phenotype of infected plasmablasts. A lack of CD138 (a plasma cell marker) and low or absent [CD20](#) (a B cell marker) is evident as well as expression of the IL-6 receptor, [CD19](#) (a B cell marker) and [CD27](#) (a memory marker). Membrane bound immunoglobulins that are exclusively IgM (heavy chain) and lambda (light chain) are also hallmarks of HHV-8 infection. In normal B cell development, NF- $\kappa$ B drives expression of lamda light chains following unsuccessful kappa gene rearrangements. However, viral infection occurs subsequent to complete immunoglobulin receptor formation, thus we see the exclusive expression of lamda light chains in infected cells. Although this process is not well understood, it is thought to be caused by viral induction of NF- $\kappa$ B transcriptional activity. Infected plasmablasts go on to lack class switching recombination because they bypass the germinal centre reactions.

HHV-8 infected plasmablasts produce cytokine growth factors



## HHV-8 infected plasmablasts produce cytokine growth factors



The long term survival of latently infected B cells is mediated by both anti-apoptotic and pro-growth factors. IL-6 plays a central role as a growth factor for infected B cells. HHV-8 infection promotes B cell expression of the IL-6 receptor which is composed of two protein chains, gp80 and gp130. HHV-8 produces viral IL-6 (vIL-6), a homologue cytokine

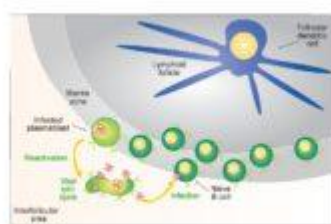
The long term survival of latently infected B cells is mediated by both anti-apoptotic and pro-growth factors. [IL-6](#) plays a central role as a growth factor for infected B cells. HHV-8 infection promotes B cell expression of the [IL-6 receptor](#) which is composed of two protein chains, gp80 and [gp130](#). HHV-8 produces viral IL-6 (vIL-6), a homologue cytokine

of human IL-6. vIL-6 signals through the gp130 chain, but does not need to bind to gp80 to activate cells. Although vIL-6 is expressed at high levels during lytic replication, latently infected B cells express low levels which stimulate the IL-6 receptor (IL6R or CD126) in an autocrine and paracrine manner to provide growth signals to the infected plasmablasts. Infected B cells also express human IL-6, due to NF- $\kappa$ B activation, which binds the IL-6 receptor and promotes survival and polyclonal B cell proliferation and increased immunoglobulin production. In our case study, the increase in the levels of human IL-6 and vIL-6 in the patient gives rise to his presenting symptoms i.e. fever, malaise, wasting, lymphadenopathy and hepatosplenomegaly.

Immune dysfunction increases reactivation of latent HHV-8

immunopaedia.org

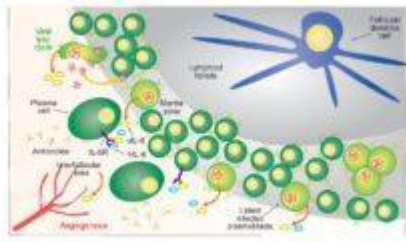
## Immune dysfunction increases reactivation of latent HHV-8



In healthy immunocompetent hosts, entry of infection is usually asymptomatic. Due to restriction of virus to already infected cells, reactivation to replenish reservoirs and promote transmission to new hosts occurs periodically. When the immune system becomes dysfunctional, such as in HIV infection, immune surveillance to limit the latent reactivation of virus is compromised. This results in increased levels of replication and virus "burden". Larger numbers of infectious virus in lymph nodes promote abnormal levels of polyclonal B cell proliferation via cytokine stimulation, particularly IL-6, resulting in lymph node enlargement (lymphadenopathy).

In healthy immunocompetent hosts, HHV-8 infection is usually asymptomatic, due to immune control of virus infected cells. Reactivation to replenish viral reservoirs and promote transmission to new hosts occurs periodically, but is limited. However, when the immune system becomes dysfunctional, such as in HIV infection, immune surveillance by T cells and subsequent ability to limit reactivation of virus is compromised. This results in increased levels of replication and infection of more B cells. Larger numbers of infected B cells in lymph node follicles can promote abnormal levels of polyclonal B cell proliferation via cytokine stimulation, particularly IL-6 as discussed above, with resulting lymphoid hyperplasia.

IL-6 production stimulates B cell proliferation.

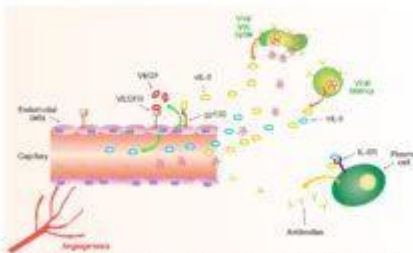


Polyclonal B cell proliferation associated with Castleman's disease is mediated by increased levels of IL-6. Immune dysfunction results in increased reactivation of latent virus reservoirs which in turn increases levels of viral latent infected plasmablasts that localise to the mantle zone produce vIL-6 as well as human IL-6. Although human IL-6 is a more potent activator of the IL-6 receptor, viral IL-6 only needs to engage the gp130 chain of the receptor to induce signaling. Gp130 is expressed on a wider range of cells than the full IL-6 receptor (gp130 and gp80), and in particular on endothelial cells. In Castleman's disease, increased levels of human IL-6 and vIL-6, soluble or plasma, as well as increased gp130 expression and increased proliferation of antibody producing plasma cells that accumulate in the interfollicular areas is also mediated by human IL-6. Activated endothelial cells produce VEGF that stimulates angiogenesis and further production of human IL-6.

## IL-6 production stimulates B cell proliferation

Polyclonal B cell proliferation associated with Castleman's disease is mediated by increased levels of IL-6. Immune dysfunction results in increased reactivation of latent virus reservoirs which in turn increases levels of viral latent infected plasmablasts that localise to the mantle zone produce vIL-6 as well as human IL-6. Although human IL-6 is a more potent activator of the IL-6 receptor, viral IL-6 only needs to engage the gp130 chain of the receptor to induce signaling. Gp130 is expressed on a wider range of cells than the full IL-6 receptor (gp130 and gp80), and in particular on endothelial cells.

vIL-6 activation of endothelial cells



Thus vIL-6 can activate endothelial cells via gp130 binding, which then produces vascular endothelial growth factor (VEGF), which stimulates angiogenesis and further production of human IL-6. These elevated systemic levels of IL-6 are then associated with many of the symptoms of Castleman's disease.

Thus vIL-6 can activate endothelial cells via gp130 binding, which then produces vascular endothelial growth factor (VEGF), which stimulates angiogenesis and further production of human IL-6. These

elevated systemic levels of IL-6 are then associated with many of the symptoms of Castleman's disease.

## Download images for this case



### [Castleman's Disease](#)

1 file(s) 2.24 MB

[Download](#)

## Treatment

ART was commenced

Chemotherapy: CHOP ([cyclophosphamide](#), [daunorubicin](#), [vincristine](#) and [prednisone](#)) and [rituximab](#) (anti CD20 monoclonal antibody)

Although not used to treat the patient in this case study new drugs that target IL-6 have been developed and are being tested in patients with MCD.

- [Tocilizumab](#) (Actemra®), is a monoclonal antibody that blocks the action of IL-6 by binding to its receptor on lymphocytes. Currently approved for treatment of rheumatoid arthritis in the United States, there has been some success in its off label use in patients with MCD.
- [Siltuximab](#), also a monoclonal antibody, targets IL-6 itself. This drug has been approved by the FDA and EMA for treatment of MCD.

## Download images for this case



## [Castleman's Disease](#)

1 file(s) 2.24 MB

[Download](#)

### **Final Outcome**

The patient's clinical course showed a favourable response. At his 6 month review he is shown to be in remission.

CD4 count is now 400 cells/mm<sup>3</sup>

HHV8 viral load is less than detectable level

### **Download images for this case**



## [Castleman's Disease](#)

1 file(s) 2.24 MB

[Download](#)

### **References**

Saeed-Abdul-Rahman I and Al-Amri AM. (2012) Castleman disease. Korean J Hematol. 2012 Sep;47(3):163-77.

[Link to abstract](#)

Uldrick TS, Polizzotto MN, Yarchoan R (2012). Recent advances in Kaposi sarcoma herpesvirus-associated multicentric Castleman disease. Curr Opin Oncol. 2012 Sep;24(5):495-505.

[Link to abstract](#)

Polizzotto MN, Uldrick TS, Hu D, Yarchoan R (2012). Clinical Manifestations of Kaposi Sarcoma Herpesvirus Lytic Activation: Multicentric Castleman Disease (KSHV-MCD) and the KSHV

Inflammatory Cytokine Syndrome. Front Microbiol. 2012 Mar 2;3:73

[Link to abstract](#)

El-Osta HE, Kurzrock R (2011). Castleman's disease: from basic mechanisms to molecular therapeutics. Oncologist. 2011;16(4):497-511.

[Link to abstract](#)

Derudder E, Cadera EJ, Vahl JC, Wang J, Fox CJ, Zha S, van Loo G, Pasparakis M, Schlissel MS, Schmidt-Supprian M, Rajewsky K (2009) Development of immunoglobulin lambda-chain-positive B cells, but not editing of immunoglobulin kappa-chain, depends on NF-kappaB signals. Nat Immunol. 2009 Jun;10(6):647-54.

[Link to abstract](#)

Wyplosz B et al (2008). Initial human herpesvirus-8 rash and multicentric Castleman disease. Journal of Clinical Infectious Disease. 2008 Sep 1;47(5):684-8

[Link to abstract](#)

## Download images for this case



## [Castleman's Disease](#)

1 file(s) 2.24 MB

[Download](#)

## Evaluation – Questions & answers

**What is the diagnosis?**

Multicentric Castleman's disease (MCD), a lymphoproliferative

disorder.

**Which cell does the HHV-8 virus target?**

B cells

**What virus is associated with MCD?**

Human herpesvirus-8 (HHV-8)

**What happens to the virus once it has entered its target cell in an immunocompetent host?**

The virus will typically remain latent. This latent infection is characterised by maintenance of viral episomes in the nucleus with only a minimal expression of viral genes occurring, thus promoting long term survival of infected cells and their escape from immune surveillance. Persistence is facilitated by chronic reactivation of these latently infected cells but the resulting infection is typically asymptomatic. Viral persistence is life long.

**What happens to the virus once it enters an immunodeficient host?**

When the immune system becomes dysfunctional, such as in HIV infection, immune surveillance by T cells and subsequent ability to limit reactivation of virus is compromised. This results in increased levels of replication and new infections. Larger numbers of infected B cells in lymph node follicles can promote abnormal levels of polyclonal B cell proliferation via cytokine stimulation, particularly IL-6, with resulting tumour development and proliferation of constitutional symptoms.

**Download images for this case**



**[Castleman's Disease](#)**

1 file(s) 2.24 MB

[Download](#)

## Multiple Choice Questions

Earn 1 HPCSA or 0.25 SACNASP CPD Points  
– [Online Quiz](#)

Download images for this case



### [Castleman's Disease](#)

1 file(s) 2.24 MB

[Download](#)